Restoration of Rotated and Discolored Maxillary Incisors with a Zirconia All-Ceramic System: A Case Report

Yeon-Wha Baek, Young-Jun Lim, Myung-Joo Kim, Ho-Beom Kwon

Department of Prosthodontics and Dental Research Institute, School of Dentistry, Seoul National University, Seoul, Korea

Recently, the demand for esthetic improvement by a treatment neither time consuming nor invasive is increasing. The patient wanted the maxillary anterior teeth appearance to be improved by prosthetic treatment, not other treatments such as orthodontic, periodontal, and endodontic treatments, despite the limit of esthetic improvement. In this case, among the recent variety of all ceramic systems for the aesthetic prosthetic restoration, we selected the zirconia-based system as a method of restoration in order to conceal the discoloration of teeth. The patient was satisfied with the esthetic results.

Key word: all ceramic crown, esthetics, discoloration, zirconia

(**Journal of Dental Rehabilitation and Applied Science** 2013:29(1):95~101)

INTRODUCION

The restorations of maxillary anterior teeth are one of the esthetic challenges in fixed restorations. Proper shade selection, choice of ceramic system, and appropriate communication with the dental technicians are combined factors for success[1]. The developments in dental materials and increased patient demand for appearance have led to the introduction of many different restorative systems for all-ceramic fixed dental prostheses[2]. These metal-free crowns are considered an alternative solution because of their enhanced esthetics, biocompatibility, and inertness, and they appear to be replacing metals as the core material of choice for crowns[3].

The increasing interest in the patient's appearance has increased the demand for esthetic improvement. However, because of the long treatment period, orthodontic bracket bonding, and invasive procedure, patients prefer esthetic improvement through prosthosontic treatment rather than orthodontic treatment.

During the last decade, densely sintered zirconia-based restorations have become available. These

Correspondence to : Young-Jun Lim, DDS,MSD,PhD
Department of Prosthodontics School of Dentistry, Seoul National University
28 Yeongeon-dong, Jongno-gu, Seoul 110-749, Korea
Tel: 82-2-2072-2940, Fax: 82-2-2072-3860, E-mail: limdds@snu.ac.kr
Received: August 28, 2012, Last Revision: March 3, 2013, Accepted: March 25, 2013

ceramic systems utilize yttrium-tetragonal zirconia polycrystal (Y-TZP or partially stabilized zirconia). This material appears to have superior mechanical properties, high flexural strength and toughness to allow for the fabrication of anterior and posterior crowns and fixed partial denture[4]. However, where adequate translucency is critical for optimal esthetics, zirconia-containing core materials may not be suitable for artificial crowns. It is very important for the clinician to select the appropriate all ceramic systems by understanding their individual characteristics in achieving both a desirable treatment result and patient satisfaction.

The following case presents a patient who has the rotated and discolored 2 maxillary incisors as a chief complaint. This patient desires esthetic improvement using only prosthodontic treatment, without orthodontic treatment, bleaching, and gingivectomy. This clinical report describes the procedures used for the restoration of maxillary incisors with the zirconia-based Cercon system.

CASE REPORT

A 23-year-old male patient was referred for treatment to improve the appearance of his maxillary anterior teeth, which were unesthetically altered due to rotation and discolorations (Fig. 1). The patient had a dental history of a root canal therapy on the maxillary left and right central incisors as well as amalgam core restoration due to trauma 8 years ago. The clinical examination revealed a labioversion of the left central incisor and discolorations of both central incisors. The gingival height showed the appearance of asymmetry between the maxillary left and the right central incisor. The patient requested the improvement of his discolored teeth and teeth arrangement as his chief complaint and desired the most concise and price-conscious treatment possible.

Treatment alternatives were presented, and informed patient consent was obtained, including orthodontic treatment and periodontal surgery such as gingivectomy. The tooth reduction was too excessive for prosthetic restoration to suffice in improving teeth arrangement, so we recommended orthodontic treatment coupled with non vital bleaching; however, the time-consuming and expensive nature of these treatments led the patient to request minimal prosthodontic treatment. The asymmetry of gingival height was still observable after the diagnostic wax-up (Fig. 2), but under the patient's agreement, it was decided that the patient would be treated with #11, 21 full veneer crown restoration. Radiographic evaluation revealed that the



Fig. 1. Preoperative intraoral view. Notice the discoloration and labioversion of central incisors.

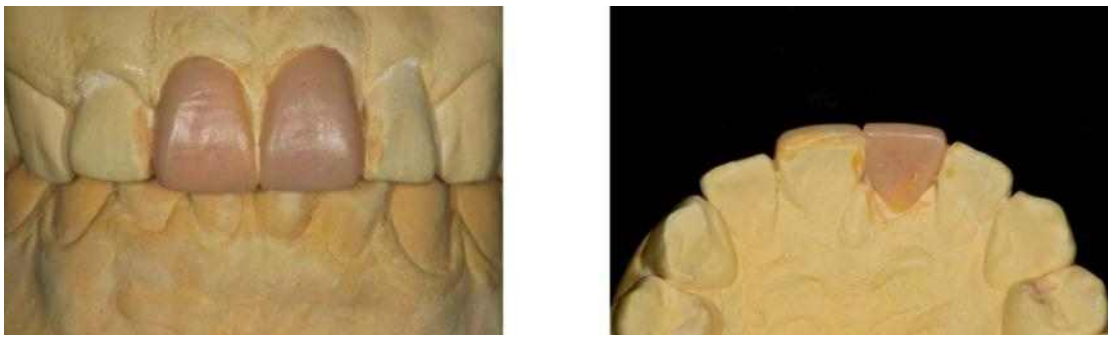

Fig. 2. Diagnostic wax-up

former had been fitted with an amalgam core after endodontic treatment.

Taking the patient's age and chief complaint into account, a treatment plan was developed that included restoring the affected teeth with zirconia-based all ceramic crowns (Cercon Smart Ceramics, Dentsply Ceramco, York, PA, USA) in order to conceal the teeth discoloration. We conducted sufficient facial tooth reduction to secure the thickness of the restoration for discolored teeth masking (Fig. 3). The shade was determined with a shade guide (Vita Lumin Shade Guide, Vident, Brea, CA, USA). Prior to the construction of the final prosthesis, the provisional restorations were fabricated with a Luxatemp®(DMG GmbH, Hamburg, Germany) (Fig. 4).

About two weeks after this procedure, the copings were fabricated with zirconia and veneered with a compatible porcelain system (Ceramco, Dentsply Ceramco, York, PA, USA). The prosthesis was airborne-particle abraded with 50-μm aluminum oxide, treated with a bonding/silane coupling agent and cemented with a resin luting cement (Rely X Unicem, 3M ESPE ,Cottage Grove, MN, USA) (Fig. 5). After completion of the treatment, the patient was recalled at six-month intervals. At the one-year follow-up appointment, the restorations were intact, no adverse effects were noted, and the resultant appearance was highly satisfactory for the patient.

Classically, the porcelain fused metal crown that



Fig. 3. Labial view of prepard teeth and shade guide in place.



Fig. 4. Provisinals in situ. A frontal view (left) and lingual view (right).

DISCUSSION



Fig. 5. Postoperative intraoral view. The definitive, all-ceramic crown in place

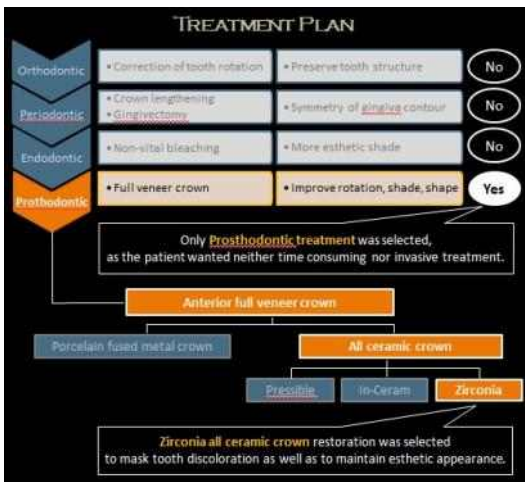

Fig. 6. Treatment plan flow chart.

has been used in for esthetic restoration has limitations in color reproduction to the natural truth due to the metal exposure in the marginal portion and the unnecessary reflection resulting from the light of the opaque layer[5]. Created to overcome these limitations, the all ceramic crown does not have a metal framework in the inner part, so during porcelain build-up the opaque layer is not used for masking the metal, thereby increasing translucency and aesthetic value[6].

Currently available all ceramic systems can be categorized broadly into two groups: those that are translucent and those that consist of an opaque, high-strength core onto which esthetic layering

ceramic must be applied to achieve a natural appearance[7]. Many ceramics, such as spinel, alumina, and ceramic reinforced with lithium disilicate, have been proposed for the construction of metal-free restorations[8]. In addition, zirconia based all ceramic restorations are popular in the market recently.

Upon looking at recent research about these products, the aesthetic value and translucency is higher for heat-pressed glass ceramic or alumina rather than zirconia, which is superior in strength[9]. According to other reports that observe the translucency of the core, the translucency declines from heat-pressed glass ceramic to alumina and to zirconia and the masking ability is superior[10].

Recently, a computer-assisted design/computer-assisted manufacturing produced, Y-TZP?based systems are in considerable demand in esthetic and stress-bearing regions. Undoubtedly, these systems are considered to be prospective replacements for metal-ceramic restorations. Cercon is a CAD/CAM system designed for the creation of anterior and posterior crowns and fixed partial dentures. The fabrication of a zirconia coping or framework with this system requires 4 main steps:(1) scanning the dies, (2) computer assisted design of the substructure, (3) automated milling of the zirconia block, and (4) sintering. Next, the substructure is veneered with compatible feldspathic porcelain to achieve the desired contour and esthetics.

All ceramic crowns have been extensively used in prosthodontics in recent years for their superior gingival response and esthetic quality[3]. However, when considering use of all ceramic restorations, clinicians should understand that all systems are not the same. One important physical property for zirconia is that zirconia has not only a color similar to teeth but is also opaque[4]. This can be an advantage for the clinical situation when a dischromic tooth or a metal post must be covered, a zirconia core arrows concealment of this unfavorable aspect.

The patient shows signs of discoloration and abnormality of teeth arrangement and sought to remedy these problems. The original treatment plan was to improve teeth arrangement with orthodontic treatment and all ceramic crowns after amalgam core removal, nonvital bleaching, and resin core build-up, but we chose to treat the patient with prosthetic restoration despite the aesthetic limitations due to the patient's request for a minimal price and minimal time treatment.

In this case, in order to block teeth discoloration and amalgam core, we selected the zirconia treatment for its superior masking ability. The detailed flow chart of the treatment plan is shown in Figure 6.

CONCLUSION

In this case, all ceramic crown restoration not combined with other treatments was performed, because patient wanted neither time consuming nor invasive treatment. The patient was satisfied with this limited esthetic improvement, as he was informed of various treatment options and the limit of each treatment result before treatment. For esthetic prosthetic restoration, various ceramic systems have been developed to reinforce both strength and esthetics. Clinicians are required to understand the own distinct character and indication of each system in order to select an appropriate one for the patient's situation

REFERENCES

1. Kahng LS. Patient-dentist-technician communication within the dental team: Using a colored treatment

plan wax-up. J Esthet Restor Dent. 2006;18(4): 185-93; discussion 194-5.
2. Lawn BR, Pajares A,Zhang Y, et al. Materials design in the performance of all-ceramic crowns. Biomaterials 2004;25:2885?92.
3. Polack MA. Restoration of maxillary incisors with a zirconia all-ceramic system: a case report. Quintessence Int. 2006;37:375-80.
4. Komine F, Blatz MB, Matsumura H. Current status of zirconia-based fixed restorations. J Oral Sci. 2010;52(4):531-9.
5. Fradeani M, Redemagni M. An 11-year clinical evaluation of leucite reinforced glass-ceramic crowns: a retrospective study. Quintessence Int 2002;33: 503-10.
6. Jung RE, Sailer I, H?mmerle CH, Attin T, Schmidlin P. In vitro color changes of soft tissues caused by restorative materials. Int J Periodontics Restorative Dent. 2007;27:251-7.
7. Spear F, Holloway J. Which all-ceramic system is optimal for anterior esthetics? J Am Dent Assoc. 2008 Sep;139 Suppl:19S-24S.
8. Raigrodski AJ. Contemporary materials and technologies for all-ceramic fixed partial dentures: a review of the literature. J Prosthet Dent. 2004;92:557?62.
9. Heffernan MJ, Aquilino SA, Diaz-Arnold AM, Haselton DR, Stanford CM, Vargas MA. Relative translucency of six all-ceramic systems. Part I: Core materials. J Prosthet Dent .2002;88:4-9.
10. Chu FCS, Chow TW, Chai J. Contrast ratios and masking ability of three types of ceramic veneers. J Prosthet Dent 2007;98:359-64.

지르코니아 완전도재 수복 방법을 사용한 회전되고 변색된 상악중절치의 수복

서울대학교 치의학대학원 치과보철학 교실

백연화 · 임영준 · 김명주 · 권호범

최근 단시간에 비침윤적 방법으로 심미적인 개선을 바라는 치과 치료에 대한 요구가 증가하고 있다. 환자는 심미성의 한계에도 불구하고 교정, 치주, 신경치료 없이 보철적 치료방법만으로 상악 전치부의 심미적 개선을 원하였다. 이 증례에서는 최근에 소개된 여러 종류의 완전도재수복방법 중에서 변색된 치아를 차단하기 위해 지르코니아를 이용한 수복방법을 선택하였으며, 만족된 결과를 얻었다.

주요어: 완전도재수복물, 심미성 지르코니아, 변색, 지르코니아

교신저자: **임영준**
서울대학교 치의학대학원, 치과보철학교실,
서울특별시 종로구 연건동 28번지,110-749, 대한민국
Fax: 82-2-2072-3860, E-mail: limdds@snu.ac.kr
원고접수일: 2012년 8월 28일, 원고수정일: 2013년 3월 10일, 원고채택일: 2013년 3월 25일