Orthodontic Treatment Combined with Occlusal Splint in Regressive Condyle Resorption Patients

Ki-Chul, Tae

Department of Orthodontics, Wonkwang University

INTRODUCTION

The key role of normal temporomandibuar joint(TMJ) function depends on the active role of the articular disc in maintaining joint stability, and a friction-free, noise-free, and pain-free condition throughout all movement of mandible.[1] If normal TMJ functions are altered by acute macrotrauma, chronic microtrauma, or developmental and acquired defect, it induces a pathologic change in TMJ.[2] The symptoms of pathologic change in TMJ are clicking sounds, pain, muscle tenderness, and mouth opening limitation, all of which are considered to be characteristics of an internal derangement (ID) of the TMJ.[3] ID is often induces for regressive change, frequently of traumatic origin, and it is often responsible for secondary change in occlusion, facial deformity, or both.[4,5] In orthodontics today, orthodontic treatment of TMD patients is still a very difficult and controversial theme.

Various researches have reported that the incidence of TMD may vary from 25% to 50%, according to the particular study.[6] For diagnosis of TMD, using a magnetic resonance imaging (MRI) and computerized tomogram (CT) allows for easy determination and to reassess the treatment result.[7] Especially, CT is useful to monitor the regressive bony change in TMJ.

Rapid regressive change in the TMJ commonly leads to the disc derangement and the loss of vertical dimension. In contrast, no clinical signs may appear as a result of compensatory occlusal change in slow progressive joint alteration.[8] Without prudential consideration of preexisting TMJ changes, subsequent orthodontic treatments result in some therapeutic failures and clinical relapse.[9] The general concept of treatment in regressive condyle change consists of 2 phase therapy.[10] Phase I therapy is interested in symptomatic and functional improvement in TMJ, such as splint therapy, pharmacologic therapy, and psychologic therapy. Phase II therapy, including orthodontic treatment, is generally irreversible dental procedures, but stable sustain condyle position after phase I therapy is difficult during orthodontic treatments without a splint. This article reports the occlusal splint combined orthodontic treatment in regressive condyle resorption patients to avoid excessive joint loading and to sustain stable mandibular position after phase I therapy.

*2006년도 원광대학교 교비 지원을 받음

Case 1

The patient was a man, 18 years 5 months old, who had a orthodontic treatment experience to relief anterior crowding with 4 bicuspid extraction therapies for 20 months. At dedonding time, his facial profile was esthetic and TMD symptoms had not appeared.

After debonding 1 year later, he reported a mouth opening limitation, joint sound, and left deviated positioning of mandible could make the mouth open. He made a joint sound by a peculiar intentional mandibular movement during orthodontic treatment and retention period. However, his centric occlusion was good(Fig. 1-A). CT showed a subcondylar cyst at the medial-superior pole of the left TMJ (Fig. 2-A, B). From those examinations, this patient was diagnosed as ID of TMJ with a subcondylar cyst. We had a 2 phase treatment plan, as follows;

*Phase 1: the occlusal splint therapy to improve mouth opening

*Phase 2: the occlusal splint combined with orthodontic treatment to maintain condylar position and to correct occlusion after phase I therapy.

The anterior repositioning splint(ARS) was the

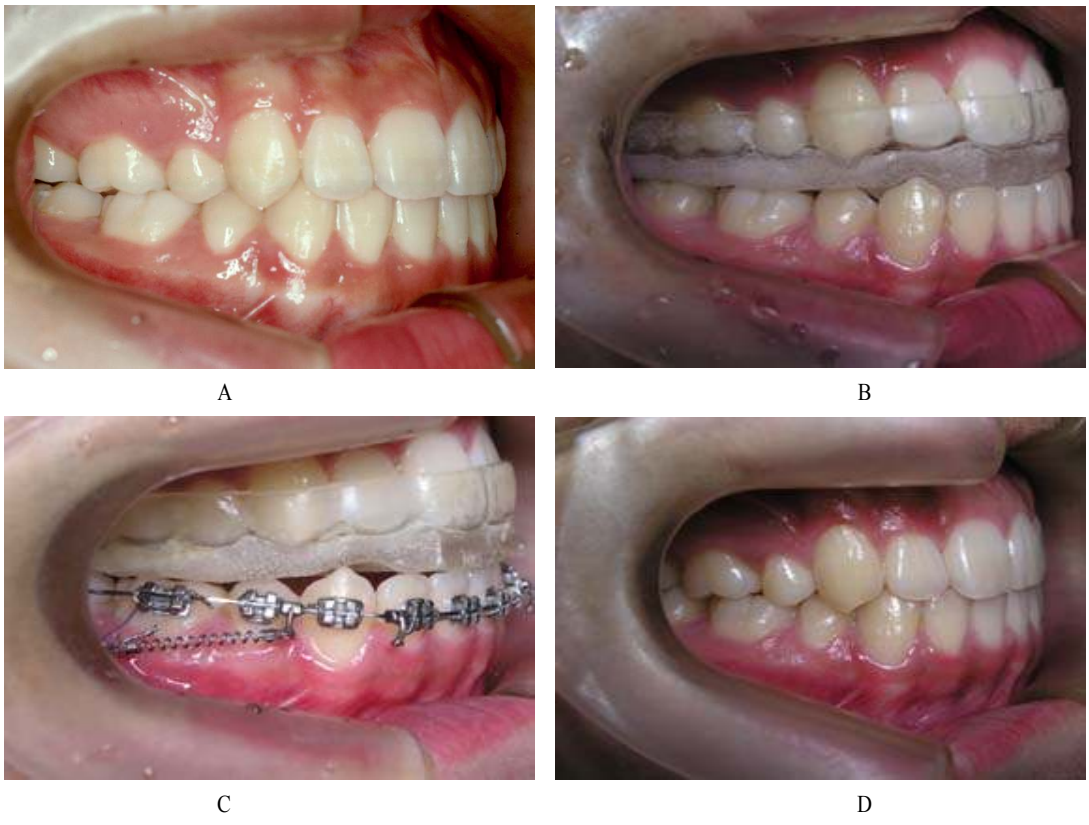

Fig. 1. Treatment sequence of orthodontic approach combined with occlusal splint in case 1
A: Before splint therapy
B: ARS used to control pain and to relieve mouth opening limitation
C: En mass retraction of lower dentition while condyle position was guided by the splint
D: Debonding stage

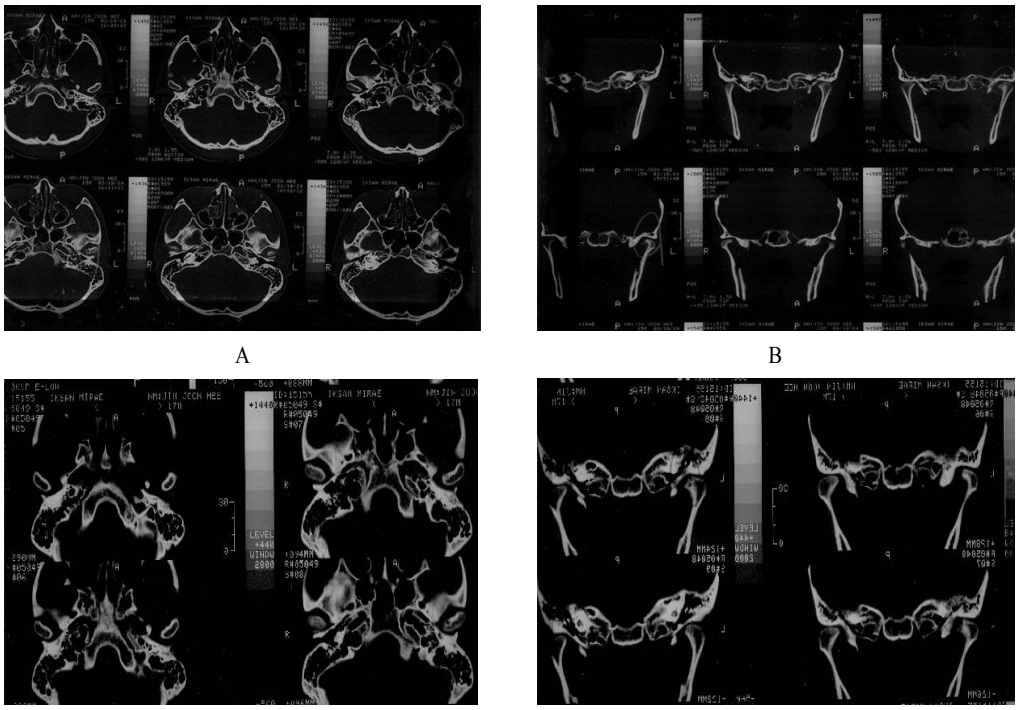

A B

C D

Fig. 2. CT showed that the size of subcondylar cyst at left condyle was not increased.
A-B: Pretreatment
C-D: Posttreatment

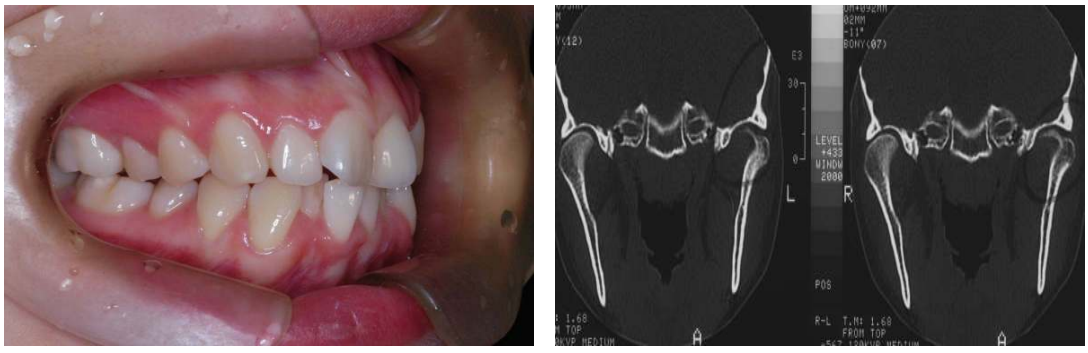

A B

Fig. 3. Pretreatment photograph in case 2
A: Anterior crowding in the both arch
B: The condyle resorption at left side was showed in CT view

initial therapy for pain control and to improve mouth opening limitation(Fig. 1-B). It was converted to centric repositioning splint(CRS) as the TMD symptoms improved. We recommended for the patient to always wear the splint to maintain the improved condyle position and to decrease the load to the TMJ. Four months after splint therapy, the mouth opening limitation and TMJ pain disappeared. Then, orthodontic treatment with miniscrews and multibrackets was initiated. One miniscrew(6mm, ®Jeil, Korea) was inserted between #36 and #37, the other was between #45 and #46 (Fig. 1-C). The purpose of the screws was for anchorage to pull back lower dentition without effecting condyle position. After en mass retraction of lower dentition was accomplished, we removed the splint for occlusal settling. He had a very low grade sound on the left TMJ, but pain and mouth opening limitation hadn't reoccurred during orthodontic treatment (Fig. 1-D) and CT showed no

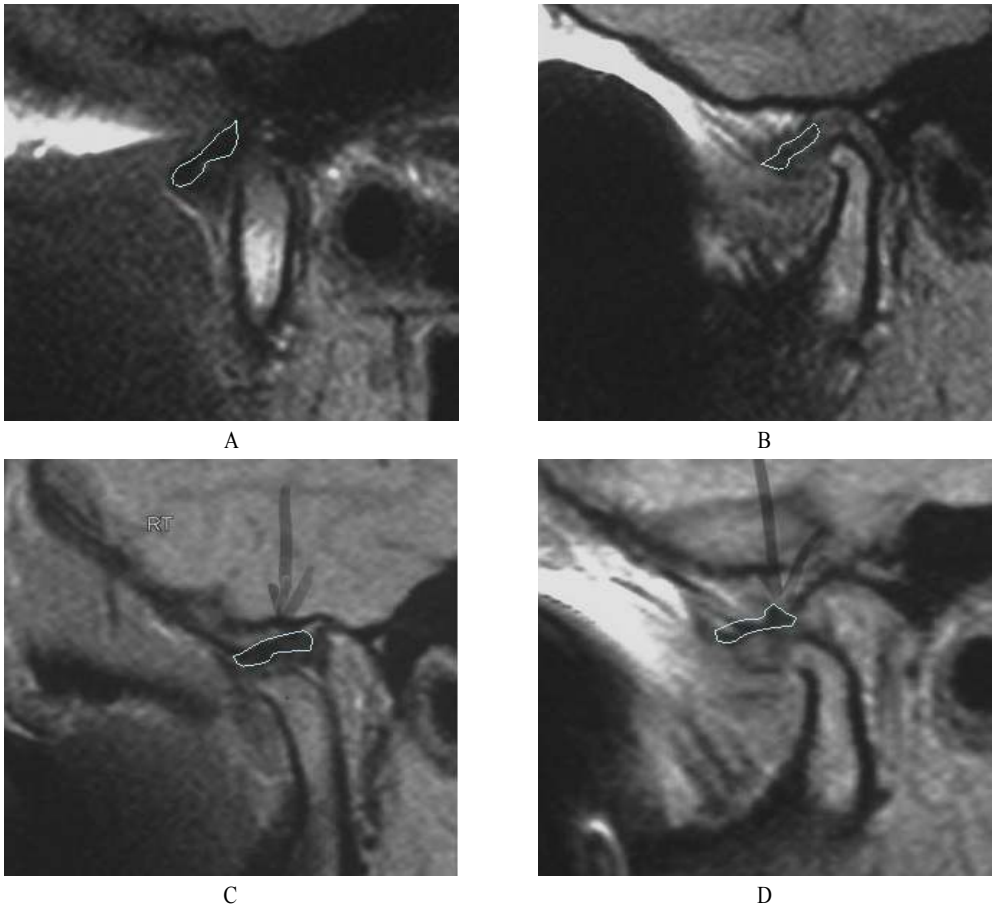

Fig. 4. MRI finding of pretreatment in case 2

A: Anterior disc displacement at mouth closing condition of right TMJ

B: Anterior disc displacement at mouth closing condition of left TMJ

C: Disc reduction at opening condition of right TMJ

D: Anterior disc displacement at mouth opening condition of left TMJ

enlarged configuration of subcondylar cyst at the debonding stage (Fig. 2-C,D). The total retreatment time was 14 months (Fig. 3).

Case 2

This patient was a woman, 16 years 3 months old, who had a predental history of TMD treatment for 2 months in department of oral medicine before orthodontic treatment. She had anterior crowding on the both dentition(Fig. 3-A), teeth #16 was decayed and the dental midline wasn't a coincidence. In a clinical exam, the mouth opening path was a jerk shape. The maximum opening position was deviated to the left side, and clicking sound and pain on both TMJ were observed. And CT showed severe resorption at the left condyle (Fig. 3-B). MRI showed that the pattern of ID was anterior disc displacement with reduction at right TMJ and without reduction at left TMJ (Fig. 4). From those examinations, she was diagnosed with skeletodental dysplasia with severe condyle resorption. We had the same treatment plan as case 1;

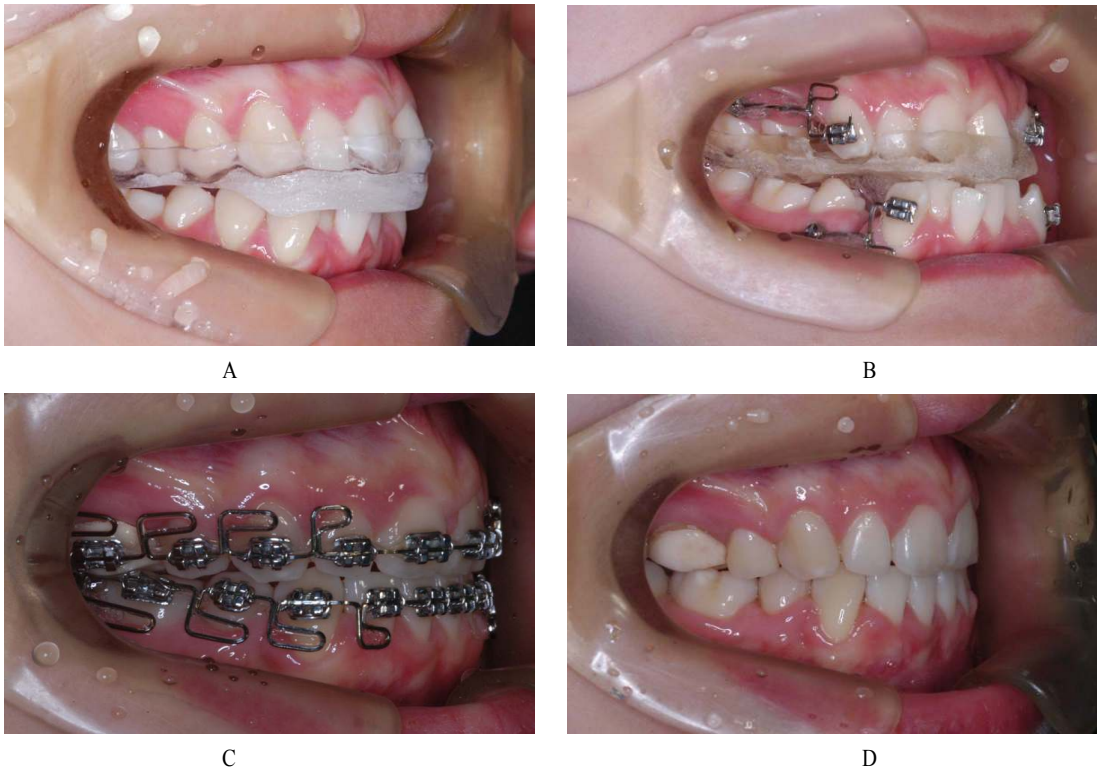

A B C D

Fig. 5. Treatment sequence of orthodontic approach combined with occlusal splint in case 2

A: Centric repositioning splint therapy

B: ARS used to recapture disc and initation orthodontic treatment with #14,24,34,44 extraqction

C: Removed ARS during finishing stage

D: Debonding stage

*Phase 1: the occlusal splint therapy to repose both condyle

*Phase 2: the orthodontic treatment combining occlusal splint with teeth #14, 24 , 34, 44 extractions

The initial splint was a CRS and we recommended full time wear of the splint (Fig. 5-A). After wearing the CRS, the mouth opening path was straight but a left deviation pattern remained during maximum opening, and an anterior

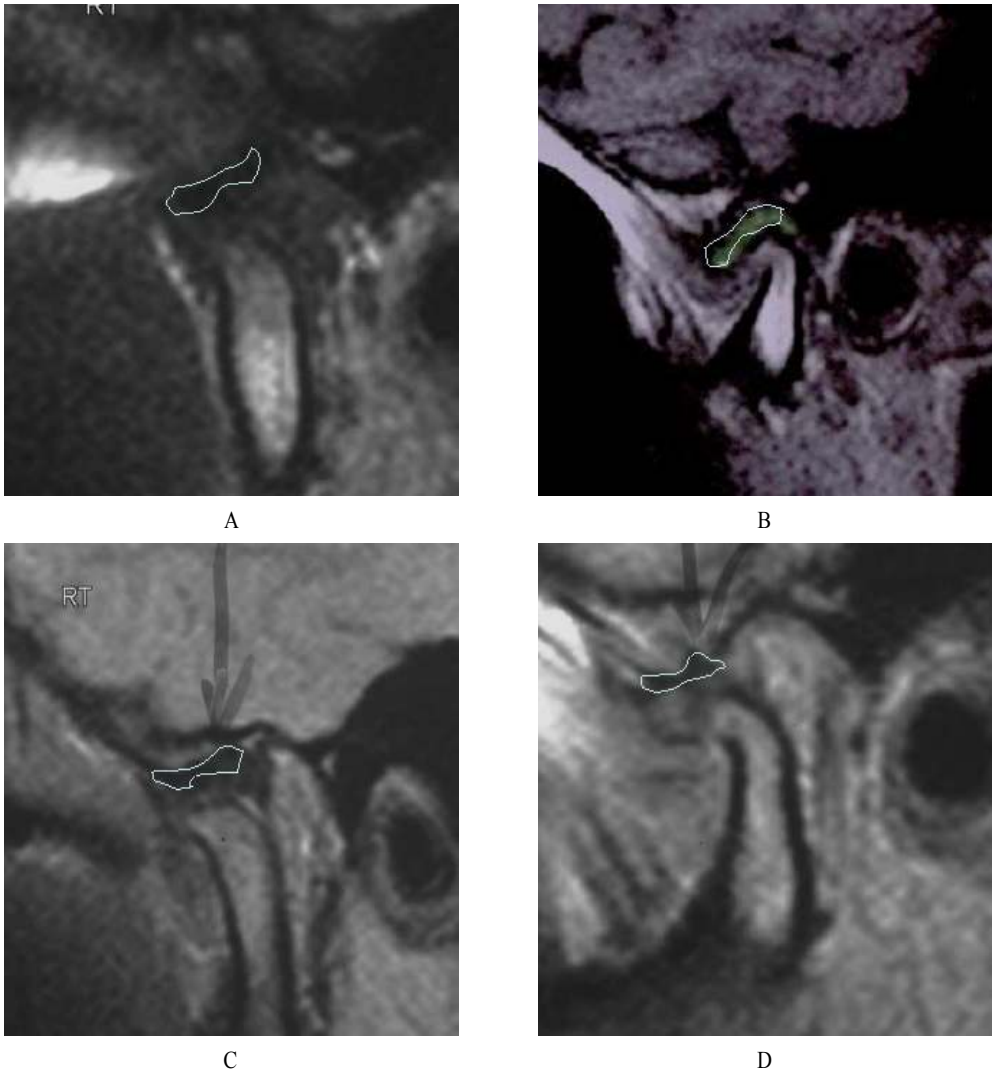

A B C D

Fig. 6. MRI finding of posttreatment in case 2

A: Normal position of disc at mouth closing condition of right TMJ

B: Normal position of disc at mouth closing condition of left TMJ

C: Normal position of disc at opening condition of right TMJ

D: Normal position of disc at mouth opening condition of left TMJ

open bite had increase . At 6 months after the splint therapy, orthodontic treatment combined with anterior repositioning splint was initiated as the disc recapture position achieved and the amount of anterior open bite was stabilized (Fig. 5-B). We recommended wearing a night splint during tooth movement. The splint was modified to retract upper canines and to align upper incisor . After verified the stable condyle position at the finishing stage, the occlusal splint was removed for occlusal settling (Fig. 5-C). At debonding time, molar relation was Angle's class I, occlusion was harmonized with condyle position and no TMD symptoms had occurred (Fig. 5-D). After debonding, MRI showed the position of both discs were reduction at closing and opening condition. (Fig. 6). Total treatment time was 20 months.

DISCUSSION

The normal function of TMJ is an important consideration factor to orthodontists. With TMJ relates, the treatment goals of orthodontics maintain a stable position of mandibualr condyle, to rehabilitate condyle-disc position and to maintain healthy condition of the TMJ.[11)]

An unstable position of condyle in TMJ by occlusal change, stress, and trauma progressed to TMD, which was symptomatic or asymptomatic.[12)] For definite diagnosis and to find a stage of TMD, radiographic examinations including MRI or CT and clinical examination were done. According to various causes of TMD, however, the criteria for evaluating a successful treatment remained unclear to the clinician. Also a given treatment may be effective for some signs and symptoms, but not effective for others.

The characteristics of chronic stage TMD were that the subjective symptoms were more asymptomatic and the objective signs were degenerative change.[13,14)] Although pain symptoms were eliminated during phase I therapy in a degenerative condyle condition, the clicking sound and mouth opening deviation returned after discontinuation of splint.[15)] Furthermore, the destructed condyle was not transformed to its original shape.[8)] Therefore there were some questions to treat in regressive condyle patients, i.e .which was the best treatment modality?, what was an effective treatment forcondyle-discrelocation?, and how can we maintain the relocatedcondyle-discrelation?. Actually, the clinician had chosen the conservative and



A B

Fig. 7. Modification of CRS
A: Tripod type B: Bipod type

combination therapy rather than their reversible and single therapy for regressive TMD treatment.[16)]

In these case reports, we focused on getting stable mandible positioning and to avoid eccentric joint loading before and during orthodontic treatment by continuing an application splint. Many researchers report that a splint has the effects of altering joint loading, joint stability, and muscle function.[17-19)] And biologically, it effects condyle remodeling with increasing aggrecan synthesis.[20)] We used ARS when a TMD patient had mouth opening limitation, and used CRS for the stabilization of mandibular condyle when the patient had shown an irregular mouth opening path. When teeth movement was needed, full coverage CRS was modified with a bipod and tripod type during orthodontic treatment (Fig. 7). After a therapeutically derived position was made, the phase II therapy initiated. Any causative factors that might perpetuate the symptoms should be eliminated during phase I therapy, if possible. We recommended wearing a splint at nighttime during phase II therapy for occlusal settling. At finishing time, the splint was taken away from the dentition for occlusal detailing. A long term follow check, however, is needed for verification of condyle stability and condyle remodeling during retention time.

CONCLUSION

It is important for orthodontic treatment to avoid harmful joint loading and to improve muscle function in regressive condyle changed patients. An orthodontic treatment combined with occlusal splint is considered one mode to achieve those treatment objectives in relation to TMJ health.

REFERENCE

1. Roth RH, Rolfts DA. Functional occlusion for the orthodontist. Part II. J Clin Orthod 1981;15:100-123
2. Thompson JR. Abnormal function of the temporomandibular joints and related musculature; Orthodontic implication, Part I. Angle Orthod 1986;56:143-163
3. Seligman DA, Pullinger AG. The role of functional occlusal relationships in temporomandibular disorders: A review. J Craniomandib Disord 1991;5:265-279
4. Emshoff R, Rudisch A. Are internal derangement and osteoarthrosis linked to changes in clinical outcome measures of arthrocentesis of the temporomandibular joint? J Oral Maxillodfac Surg 2003;61:1162-1167
5. Haskin CL, Milam SB, Cameron IL. Pathogenesis of degenerative joint diseases in the human temporomandibular joint. Crit Rev Oral Biol Med 1995;6:248-277
6. Sadowsky C. The risk of orthodontic treatment for producing temporomandibualr disorders: A literature overview. Am J Orthod Dentofac Orthop 1992;101:70-83
7. Milbauer DL. Magnetic resonance imaging and computerized tomography. In KaplanAS,AssaelL Aeditors.Temporomandibulardisorders.Saunders;1991. p353-370
8. Schellhas KP. Internal derangement of the temporomandibular joint: radiologic staging with clinical, surgical and pathologic correlation. J Magn Reson Imag 1989;7:495-515
9. Kamelchuk LS, Major PW. Degenerative disease of the temporomandibular joint. J Orofac Pain 1995;9: 168-180
10. Friction j, Hathaway k, Bromaghim C. Interdisciplinary management of patients with TMJ and craniofacial pain; Characteristics and outcome. J Craniomandib Prac 1987;1:115-122
11. McNamara JA Jr, Seligman DA, Okeson JP. Occlusion, orthodontic treatment, and temporomandibular disorders: A review. J Orofac Pain 1995;9:73-90
12. Freeland T, Kulbersh R. Orthodontic therapy using the Roth gnathologic approach. Semin Orthod 2003;9:140-150
13. Schellhas KP. Unstable occlusion and temporomandibualar joint disease. J Clin Orthodont 1989;23: 332-337
14. Wilkes CH. Internal derangement of the temporoman-

dibualar joint; pathologic variations. Arch Otolaryngol Head Neck Surg1989;115:469-477
15. Okeson JP. Long-term treatment of disc-interference disorders of the temporomandibualr joint with anterior repositioning occlusal splints. J Prosthet. Dent 1988;60:611-616
16. Boering G, Stegenga B, de Bont LG. Temporomandibular joint osteoarthrosis and internal derangement. Part I: Clinical course and initial treatment. Int Dent J. 1990;40:339-346.
17. Tanaka E, Kikuchi K, Sasaki A, Tanne K. An adult case of TMJ osteoarthrosis treated with splint therapy and the subsequent orthodontic occlusal reconstruction: Adaptive change of the condyle during the treatment. Am J Orthod Dentofacial Orthop 2000;11:566-571
18. Kurita H, Kurashina K, Ohtsuka A, Kotani A. Change of position of the temporomanidibular joint disk with insertion of a disk-repositioning appliance. Oral Surg Oral Med Oral Pathol Oral Radiol Endod 1998;85:142-145
19. Zaag J, Lobbezoo F, Wicks DJ, Visscher CM, Hamburger HL, Naeije M. Controlled assessment of the efficacy of occlusal stabilization splints on sleep bruxism. J Orofac Pain 2005;19:151-158
20. Yen EHK, Carvalho RS. Macromolecular components of connective tissues ans their roles in determining tissue mechanical properties: In McNeil C editor. Science and practice of occlusion. Quintessence. 1997, p.111-114

Corresponding Author:Ki-Chul Tae, D.D.S., M.S.D., Ph.D.
Department of Orthodontics, Dental School, Wonkwang University 344-2 Shinyoungdong, Iksan, 570-749
Fax: 63-857-0284
E-mail: kkojii@wonkwang.ac.kr

국문초록

퇴행성 과두 흡수 환자에서 교합 안정장치 병용 교정치료

원광대학교 치과대학 교정학 교실

태 기 출

악관절 잡음과 동통,과두 흡수를 동반한 퇴행성 측두하악장애는 교합 불안정과 개구장애 를 동반하기도 한다. 진단을 위해 CT나 MRI를 이용해 과두 형태 및 디스크 위치를 파악하 는 것이 유용한 접근법이다. 퇴행성 측두하악관절 환자는 CT나 MRI를 이용하여 진단하고, 과두-원판 재위치와 근 기능 개선을 위해 장기간 교합 안정장치 사용이 필요하므로 교정치료 기간에 변형된 교합 안정장치의 병용이 필요하다. 이에 본 연구에서 교합 안정장치를 병용하여 교합 재구성 증례를 CT나 MRI로 고찰해 보고자 한다.

주요 단어: 퇴행성 측두하악장애, 교정치료, 교합안정장치, 교합 재구성