https://doi.org/10.14368/jdras.2024.40.2.100
ISSN 2384-4353 eISSN 2384-4272

Case Report

Space maintainer using CAD/CAM system without a band: a case report

Eun-Sook Kang*
Department of Dentistry, College of Medicine, Kosin University, Busan, Republic of Korea

Early interceptive orthodontic interventions are often started in the developing dentition to guide normal occlusion. The simplest way to prevent eruption failure from deciduous tooth loss is to fix a space maintainer such as a band and loop. Band and loop space maintainer has several problems like cement loss, demineralization, locking of the adjacent tooth, and needs to take a pick-up impression of the band. Computer-assisted design/computer-assisted manufacturing (CAD/CAM) space maintainer without band was developed to solve these problems. This case report describes successful eruption of the mandibular second premolar using CAD/CAM without a band. **(J Dent Rehabil Appl Sci 2024;40(2):100-6)**

Key words: primary dentition; space maintainer; CAD/CAM

Introduction

Primary teeth play a crucial role in mastication, pronunciation, and aesthetics and guiding the eruption of permanent teeth and maintaining space in the oral cavity in growing children.[1] The exfoliation of primary teeth and the eruption of permanent teeth have a very close temporal relationship.[2] While it is important to try to retain primary teeth until their natural exfoliation, it is inevitable to prevent premature loss, and if premature loss occurs, it must be managed to avoid undesired effects on the occlusion during the growth period.[3]

When premature loss of primary teeth and interproximal caries occurs, distal teeth drift mesially, and the resulting arch length loss causes crowding and impaction of permanent teeth and extrusion of antagonistic teeth.[4] The most effective way to prevent these problems is to promptly apply space maintainers when premature loss of primary teeth occurs.[5]

Space maintainers can be broadly classified as removable and fixed maintainers.[6] Typically, when a single primary tooth is lost prematurely, a fixed maintainer, consisting of a band and loop device made with orthodontic bands and wires, is commonly used on adjacent teeth.[7] However, multiple bands of varying sizes for specific locations are required, and a complex technique called band pick-up impression is necessary to fabricate a band and loop device. Additionally, bleeding and pain due to damage to the periodontal tissues may occur during band placement. Using a band for an extended period on immature permanent teeth that have not yet fully erupted can lead to demineralization under the band and interference with the eruption of adjacent erupting teeth.[5] Furthermore, several long-term studies have shown that band and loop devices have a success rate of less than 50% due to cement loss and breakage.[8]

Therefore, this report presents a case of retaining space for the early exfoliated mandibular right sec-

*Correspondence to: Eun-Sook Kang
Assistant professor, Department of Dentistry, College of Medicine, Kosin University, 262, Gamcheon-ro, Seo-gu, Busan, 49267, Republic of Korea
Tel: +82-51-990-5150, Fax: +82-51-241-5458, E-mail: prosth-kang@hanmail.net
Received: January 30, 2024/Last Revision: February 26, 2024/Accepted: March 25, 2024

Copyright© 2024 The Korean Academy of Stomatognathic Function and Occlusion.
©It is identical to Creative Commons Non-Commercial License.

ond primary molar's using computer-assisted design/computer-assisted manufacturing (CAD/CAM)-fabricated space maintainers in pediatric patients. This helps overcome the disadvantages associated with using bands and addresses cases where conventional methods are not feasible to take dental impressions for uncooperative pediatric patients. Thus, it allows the completion of the mandibular right second premolar's eruption without additional orthodontic treatment.

Case Report

A 7-year-old female presented with pain and an abscess in the right mandibular gingiva. Upon examination, a 1 cm swelling with pus discharge was observed in the gingival area on the buccal surface of the mandibular right second primary molar. The mandibular right second primary molar had previously undergone pulpotomy, and panoramic X-ray findings indicated radiolucency in the root apex region, leading to a diagnosis of a periapical abscess (Fig. 1). Extraction of the affected tooth was performed. Both mandibular first primary molars were still healthy, with more than two-thirds of their roots intact. However, leaving the extraction space untreated could result in mesial migration and inclination of the mandibular right first permanent molar, leading to inadequate space for the eruption of the second premolar and the potential development of a Class III malocclusion. Therefore, a space maintainer was planned and implemented.

In cases like this, where early loss of a single primary molar occurs, a band and loop device is the conventional treatment option. However, the child in this case complained of severe pain during the band fitting process and had a pronounced vomiting reflex upon impression taking, so it is impossible to make a maintainer in a conventional method.

Therefore, it was planned to fabricate a CAD/CAM-based space maintainer (NT-spacer, SmileCAD, Busan, Korea). The mandibular right first permanent and the mandibular right first primary molars were scanned using an intraoral scanner (RayiOS, Ray, Seongnam, Korea). In the CAD software, a bar-shaped space maintainer was designed, with the fixed parts attaching to the mesial and buccolingual side of the mandibular right first permanent molar and the distal and buccolingual side of the mandibular right first primary molar, connecting the two parts. To avoid interference with the maxillary functional cusp, the bar was lingually positioned (Fig. 2). A 0.4 mm thick shape-memory alloy (Nitinol) plate was cut using a laser cutter according to the designed shape and processed to create the maintainers (Fig. 3). The de-

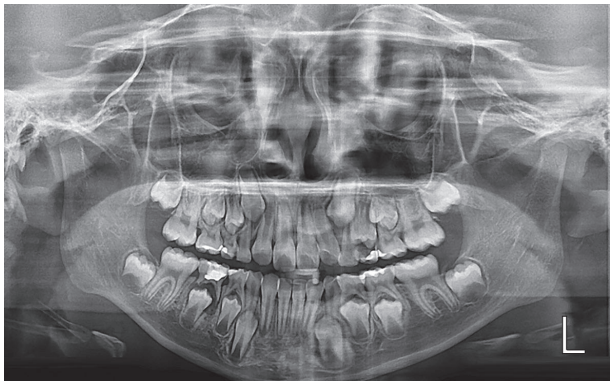

Fig. 1. Panoramic image before treatment.

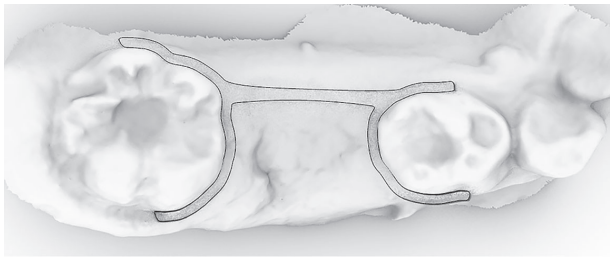

Fig. 2. NT-spacer designed in CAD.



Fig. 3. A 0.4 mm thick shape-memory alloy (Nitinol) plate was cut using a laser cutter.

vice was bonded to the teeth following the conventional etching technique and attached with flowable resin (G-fix, GC, Tokyo, Japan) that did not require a separate bonding process (Fig. 4).

After 6 months, the occlusal surface of the mandibular right second premolar showed the emergence, and the NT-spacer was removed. The child remained asymptomatic during appliance use, and no signs of gingival inflammation or tissue irritation were observed (Fig. 5). Additionally, there were no difficulties in mastication. One year later, the mandibular right second premolar eruption was completed and well-aligned (Fig. 6). It was also noted that the crowding of the mandibular anterior teeth had naturally improved compared to the time of emergence.

Discussion

While primary dentition contributes to functions such as mastication, pronunciation, occlusal growth, and aesthetics, one of its most critical roles is serving as a natural space maintainer for the subsequent permanent teeth.[6] Premature loss of primary teeth can lead to adjacent teeth shifting into the extraction space, resulting in the loss of space required for the eruption of permanent teeth. To regain the lost space, complex orthodontic treatments are often required (Fig. 7). To avoid the time and cost associated with such treatments, it is essential to use space maintainers promptly after the exfoliation of primary teeth, preserving dental arch relations before adjacent teeth shifting.[7,9]

As stated by the American Academy of Pediatric Dentistry (AAPD), space maintenance is the preservation of present dentition placement to avoid loss of arch length, width, and perimeter. After using the term "Space maintenance", in 1941, JC Brauer went on to explain that it was the process of preserving a space in the mouth that had previously been filled with one or more teeth.[10] Commonly used space maintainers are classified into removable and fixed maintainers, with removable maintainers being functional and easy to clean, making hygiene maintenance straightforward. However, they may have limitations, relying on the compliance of young patients. They can also suffer from issues such as breakage and loss. In contrast, fixed maintainers tend to reduce dependence on patient compliance, are relatively comfortable, and are easy for patients to adapt to.[9]

Fixed space maintainers usually involve the use of bands.[9] However, bands can lead to some issues. Directly bonded space maintainers, which do not require bands, eliminate issues like tooth demineralization and dental caries associated with bands. Additionally, it does not interfere with the eruption of adjacent teeth, as seen with band and loop devices. Several studies have reported successful outcomes for 6 - 12 months with direct-bonded space main-



Fig. 4. Intraoral photograph immediately after delivery.

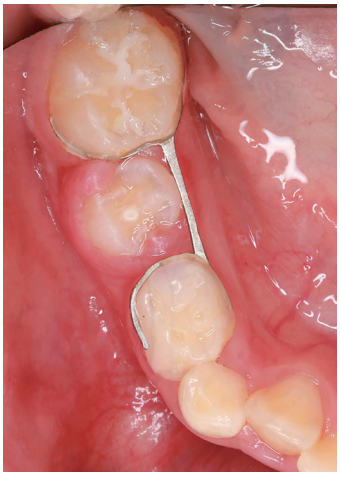

Fig. 5. Intraoral photograph 3 months after delivery.



Fig. 6. Intraoral photograph 12 months after delivery.

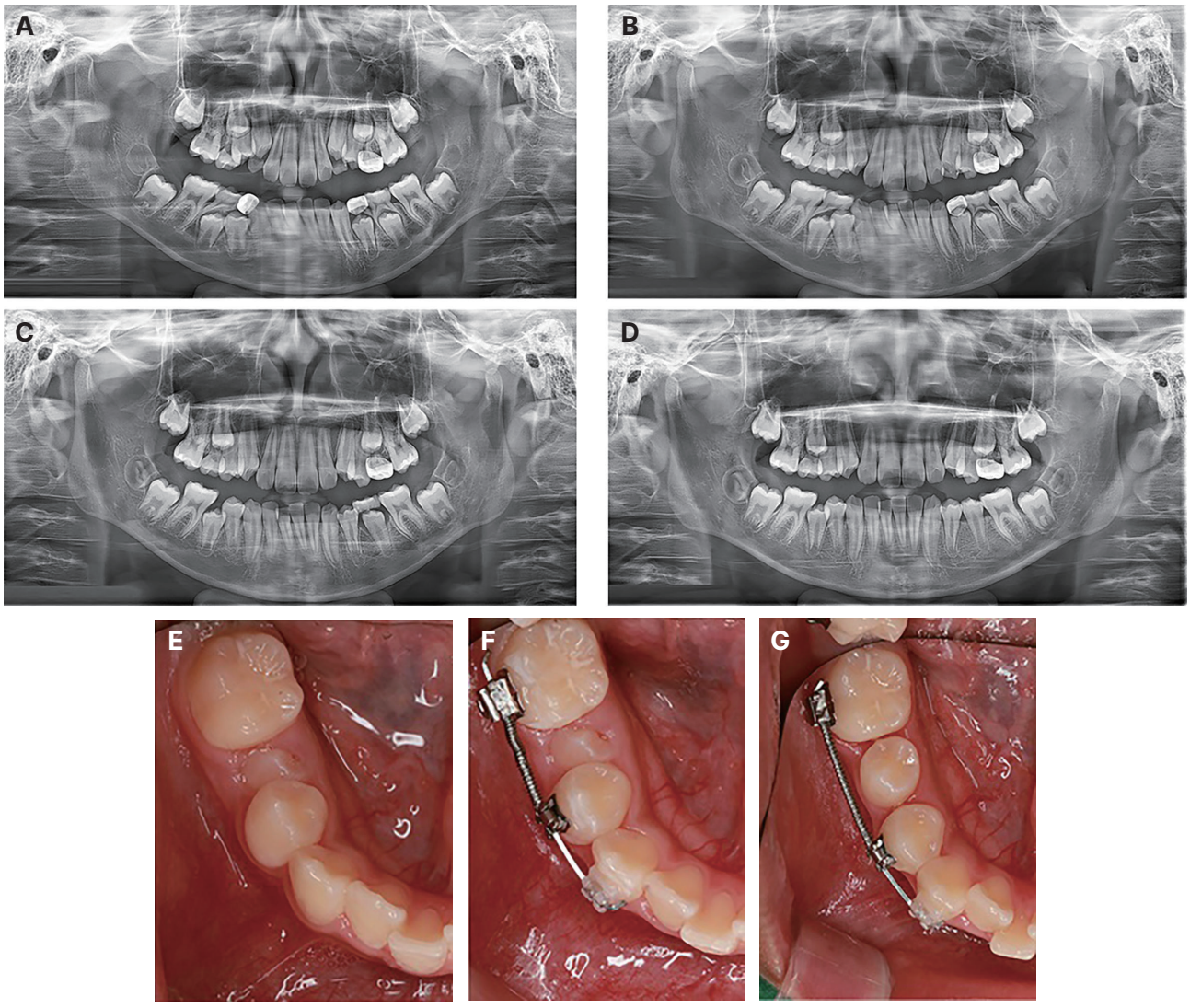

Fig. 7. Photographs before and after treatment in a patient where space had already been lost. To regain the lost space, complex and uncomfortable orthodontic treatments are required. (A) Insufficient space for eruption of tooth #43, (B) Tooth #84 has exfoliated, but there is still insufficient space for the eruption of tooth #44, (C) Insufficient space for eruption of tooth #45, (D) Additional loss of space for the eruption of tooth #45, (E) Before orthodontic treatment, (F) Start of orthodontic treatment, (G) Completion of space regaining for tooth #45 and its eruption.

tainers fabricated using round wires, stainless steel strips, or light-cured composites.[9]

With the recent advancements in CAD/CAM technology, it is possible to overcome many drawbacks associated with traditional space maintainers like the band and loop. Directly bonded space maintainers that do not require bands eliminate the need for separation procedure to secure band space, the band fitting, impression-taking, and removal process. Consequently, there is no pain, with a reduction of multiple visits to the dentist. Additionally, no waste is generated from impression and model materials, reducing labor costs.

Digital impressions are faster and more comfortable for patients. Vasudavan et al. reported that 77% of patients preferred intraoral scans over alginate impression taking.[11] Therefore, intraoral scanning can reduce the likelihood of vomiting during impression-taking procedure, making it more convenient for patients and practitioners. Moreover, intraoral scanning has been shown to provide more accurate results than impressions taken with irreversible hydrocolloid materials,[12] leading to improved appliance fit and a higher success rate.

While CAD/CAM-based space maintainers have been introduced in previous studies, they have typically been fabricated with resin or titanium materials using 3D printing,[13] or by creating a resin pattern followed by casting. However, the method of producing devices using laser-cut metal plates, as introduced in this paper, was not previously available.

CAD/CAM technology used laser-cut nitinol, as presented in this case. This method eliminates the need for wire bending, which is thought to increase the risk of wire fracture.[14,15] Additionally, the cut wire undergoes electropolishing in an ion-charged bath, resulting in a smoother wire surface. This process improves corrosion resistance, reduces susceptibility to microbial colonization, and rounds the wire's edges, increasing patient comfort.[15] Consequently, in this case, the patient could maintain the appliance without gingival inflammation, discomfort, or device breakage, ultimately leading to the successful eruption of the permanent tooth.

Despite all the benefits of CAD-CAM system, acquiring the equipment can be expensive and requires training of dental team. And the product is more expensive than the existing band & loop. Compared to the band and loop, it is concerned about possibility of fatigue destruction caused by repeated deformation and shape restoration due to the nature of the Ni-Ti wire. CAD/CAM wires are directly manufactured in the desired shape by laser cutting without wire bending could reduce the risk of deformations or micro fractures but bonding failures were reported.[14] The higher flexibility of the CAD/CAM nitinol wire leads to more occurrences of enamel-adhesive interface debondings than wire-adhesive interface debondings.[16] So the device was bonded to the teeth with flowable resin (G-fix, GC). G-fix is more resilient in physical properties than conventional composite resin, it withstands tooth fluctuations caused by chewing force and reduces the displacement of wire-shaped attachments such as fixed maintenance devices.[17]

In this case, we used 0.4 mm thickness nitinol. This is because we wanted to use a commercialized product from the company that manufactures the retainer in the same way. It is less rigid than the band and loop made using orthodontic band and 0.9 - 1.0 mm stainless steel wire, so fractures can occur occasionally. To solve this problem, we can change the material to more rigid metals such as stainless steel or make it thicker.

In the future, it is expected to be applied to prevent the loss of the implant prosthetic space, and if the interdental part is not in the form of a straight bar, but if an S-shaped spring is applied, it will be possible to expand the scope of application to a space-regainer that secures the lost space.

Survival times for bonded space maintainers in previous studies have been reported with an average of 11.2 months,[9] and bonded appliances made of orthodontic stainless steel wire have been sustained for 12 to 18 months (average = 15.6 months).[9,18] While the CAD/CAM-based space maintainer presented in this case achieved successful results, further research is needed with a larger sample size and longer-term follow-up to assess its stability and efficacy.

Conclusion

This report presents a case of retaining space for the early exfoliated mandibular right second primary molar's using computer-assisted design/computer-assisted manufacturing (CAD/CAM) fabricated space maintainers. This helps overcome the disadvantages associated with using bands and addresses cases where conventional methods are not feasible to take dental impressions for uncooperative pediatric patients. Thus, it allows the completion of the mandibular right second premolar's eruption without additional orthodontic treatment, which could be a valuable procedure for dental practitioners and patients.

ORCID

Eun-Sook Kang https://orcid.org/0000-0002-4495-4135

References

1. Barbería E, Lucavechi T, Cárdenas D, Marato M. Free-end space maintainers: Design, utilisation and

advantages. J Clin Pediatr Dent 2006;31:5-8.
2. Rao AK, Sarkar S. Changes in arch length following premature loss of deciduous molars. J Indian Soc Pedo Prev Dent 1999;17:29-32.
3. Ngan P, Alkire RG, Fields H Jr. Management of space problems in the primary and mixed dentitions. J Am Dent Assoc 1999;130:1330-9.
4. Setia V, Pandit IK, Srivastava N, Gugnani N, Sekhon HK. Space maintainers in dentistry: Past to present. J Clin Diagn Res 2013;7:2402-5.
5. Kirzioğlu Z, Ertürk MS. Success of reinforced fiber material space maintainers. J Dent Child 2004;71: 158-62.
6. Bijoor RR, Kohli K. Contemporary space maintenance for the pediatric patient. N Y State Dent J 2005;71:32-5.
7. Wright CZ, Kennedy DB. Space control in the primary and mixed dentitions. Dent Clin North Am 1978;22:579-601.
8. Qudeimat MA, Fayle SA. The longevity of space maintainers: A retrospective study. Pediatr Dent 1998;20:267-72.
9. Deshpande SS, Bendgude VD, Kokkali VV. Survival of bonded space maintainers: A systematic review. Int J Clin Pediatr Dent 2018;11:440-5.
10. Dhanotra KG, Bhatia R. Digitainers-digital space maintainers: A review. Int J Clin Pediatr Dent 2021; 14 Suppl 1:S69-75.
11. Vasudavan S, Sullivan SR, Sonis AL. Comparison of intraoral 3D scanning and conventional impressions for fabrication of orthodontic retainers. J Clin Orthod 2010;44:495-7.
12. Ender A, Attin T, Mehl A. In vivo precision of conventional and digital methods of obtaining complete-arch dental impressions. J Prosthet Dent 2016;115:313-20.
13. Tokuc M, Yilmaz H. Comparison of fit accuracy between conventional and CAD/CAM-fabricated band-loop space maintainers. Int J Paediatr Dent 2022;32:764-71.
14. Kravitz ND, Grauer D, Schumacher P, Jo YM. Memotain: A CAD/CAM nickel-titanium lingual retainer. Am J Orthod Dentofacial Orthop 2017;151:812-5.
15. Jowett AC, Littlewood SJ, Hodge TM, Dhaliwal HK, Wu J. CAD/CAM nitinol bonded retainer versus a chairside rectangular-chain bonded retainer: A multicentre randomised controlled trial. J Orthod 2023;50:55-68.
16. Gelin E, Seidel L, Bruwier A, Albert A, Charavet C. Innovative customized CAD/CAM nickel-titanium lingual retainer versus standard stainless-steel lingual retainer: a randomized controlled trial. Korean J Orthod 2020;50:373-82.
17. Yoo JI, Kim SY, Batbayar B, Kim JW, Park SE, Cho KM. Comparison of flexural strength and modulus of elasticity in several resinous teeth splinting materials J Dent Rehabil Appl Sci 2016;32:169-75.
18. Simsek S, Yilmaz Y, Gurbuz T. Clinical evaluation of simple fixed space maintainers bonded with flow composite resin. J Dent Child (Chic) 2004;71:163-8.

CAD/CAM 시스템을 이용하여 band 없이 공간유지 장치를 제작한 증례

강은숙* 조교수
고신대학교 의과대학 치과학교실

조기 교정치료의 개입은 종종 성장하는 치열을 정상 교합으로 유도하는 것에서부터 시작된다. 유치의 상실로 인한 맹출 실패를 예방하는 가장 간단한 방법은 밴드 및 루프와 같은 공간 유지장치를 부착하는 것이다. 밴드 및 루프 공간 유지장치는 밴드의 픽업 인상 과정을 거쳐야 하며, 시멘트 소실과 탈회, 인접치의 locking과 같은 문제들을 갖고 있다. 이러한 문제를 해결하기 위해서 CAD/CAM을 이용한 band가 필요 없는 공간유지장치가 개발되었다. 본 증례는 밴드 없이 CAD/CAM을 이용하여 하악 제2소구치가 성공적으로 맹출할 수 있었기에 이를 보고하는 바이다.

(구강회복응용과학지 2024;40(2):100-6)

주요어: 유치열; 공간 유지 장치; CAD/CAM

*교신저자: 강은숙
(49267)부산광역시 서구 감천로 262 고신대학교 의과대학 치과학교실
Tel: 051-990-5150 | Fax: 051-241-5458 | E-mail: prosth-kang@hanmail.net
접수일: 2024년 1월 30일 | 수정일: 2024년 2월 26일 | 채택일: 2024년 3월 25일