https://doi.org/10.14368/jdras.2024.40.4.225 Original Article
ISSN 2384-4353 eISSN 2384-4272

Three-dimensional analysis of buccally unilateral maxillary impacted canines

Eujin Jang, Dong-Hwa Chung*, Jin-Woo Lee, Sang-Min Lee, Mo-Hyeon Lee
Department of Orthodontics, College of Dentistry, Dankook University, Cheonan, Republic of Korea

Purpose: The aim was to conduct a three-dimensional comparison of impacted canines with their contralateral normal counterparts in patients exhibiting unilateral buccal impaction of the maxillary canine, utilizing the palatal plane as the benchmark reference. **Materials and Methods:** Computed tomography scans from a cohort of 31 patients diagnosed with unilateral buccal impaction of the maxillary canine were analyzed. The impacted canine was examined against the contralateral normal canine, focusing on the variables of rotation, torque, angulation, root length, and root volume. The disparities in these parameters between the left and right canines and their association with patient age were evaluated. **Results:** Notable differences were observed in rotation, angulation, torque, root length, and root volume when comparing the impacted canine to its contralateral normal counterpart. Furthermore, a significant positive correlation was identified between the age of the patients and the root length discrepancy of the impacted and contralateral normal canines. **Conclusion:** The palatal plane proves to be a viable skeletal reference for predicting the impaction of maxillary canines, with rotation, angulation, and torque serving as reliable indicators. The study further elucidates that the unilateral buccally impacted maxillary canine is characterized by a discernibly shorter root length and diminished root volume in comparison to the contralateral normal canine. **(J Dent Rehabil Appl Sci 2024;40(4):225-33)**

Key words: imaging; three-dimensional; tooth; impacted

Introduction

Maxillary canine impaction is a common challenge encountered by orthodontists in clinical practice. It is estimated that the prevalence of maxillary canine impaction ranges between 1 - 3%, with a buccal: palatal ratio in Caucasians identified as 1 : 6.[1] Contrastingly, a study conducted on a Korean population reported a higher prevalence of buccal impaction, with a ratio of 3 : 1.[2] The etiopathogenesis of maxillary canine impaction differs between buccal and palatal impactions; buccal impaction is primarily due to an arch-length discrepancy, whereas palatal impaction may be attributed to genetic factors or a lack of eruption guidance.[3]

Studies aiming to predict the impaction of maxillary canines have focused on canine angulation as a predictive factor. Power and Short suggested that if the canine's angulation to the midline exceeds 31 degrees, the likelihood of improvement diminishes.[4] Katsnelson et al. identified an association between buccal canine impaction and a canine angulation to the occlusal plane greater than 65 degrees.[5] A predictive model for canine impaction employing CBCT, which includes variables such as canine rotation and its angle to the midline and occlusal plane, was re-

*Correspondence to: Dong-Hwa Chung
Department of Orthodontics, Dankook University Jukjeon Dental Hospital, 152, Jukjeon-ro, Suji-gu, Yongin, 16890, Republic of Korea
Tel: +82-31-260-5700, Fax: +82-31-548-1071, E-mail: orthoforum@gmail.com
Received: August 21, 2024/Last Revision: September 23, 2024/Accepted: October 8, 2024

Copyright© 2024 The Korean Academy of Stomatognathic Function and Occlusion.
©It is identical to Creative Commons Non-Commercial License.

ported by Alqerban et al.[6]

The depth of canine impaction can be influenced by canine angulation.[7] Previous assessments of canine angulation, using the midline as a reference, were contingent on anterior dental relationships. Warford et al. used skeletal landmarks, such as the condyle's superior point, as a measurement reference.[8] Despite utilizing panoramic imaging, canine inclination assessments are more accurately conducted via computed tomography.[9] For children and adolescents, the primary demographic for impacted tooth treatment, CT's small field of view is preferred to reduce radiation exposure.[10] Hence, the palatal plane established in small field CT imaging could serve as a skeletal reference plane for gauging canine angulation. Zeno and Ghafari suggested that the severity of palatal canine impaction could be discerned through inclination measurements like the canine angulation to the palatal plane.[11] Nevertheless, research on buccally impacted canines remains sparse.

Moreover, impacted maxillary canines experience restricted root development either within the floor of the nose or against the maxillary sinus cortical bone,[1] potentially hindering growth due to nearby anatomical structures. Thus, early intervention plays a crucial role in the development of the maxillary canine root.[12] The canine root length in cases of buccal impaction was found by Dekel et al. to be significantly shorter than its contralateral counterpart, by an average of 1.3 mm.[1] Conversely, Silva et al. found no substantial difference in root length between impacted canines and their contralateral sides.[13] Hettiarachchi et al. reported that the average root length of palatally impacted canines was shorter by 2.6 mm than the contralateral side.[14] However, Leonardi et al. observed no significant disparities in the length and volume of palatally impacted canines when compared to the contralateral side.[15]

In light of these considerations, it becomes apparent that three-dimensional assessments of buccally impacted maxillary canines using a skeletal reference line are limited. Furthermore, available studies on the root development of impacted canines yield conflicting outcomes. Consequently, this study aims to assess the three-dimensional position and root morphology of unilateral buccally impacted canines, comparing them with the contralateral side by utilizing cone-beam computed tomography.

Materials and Methods

This study involved patients diagnosed with unilateral buccal impaction of maxillary canines at the Dankook University Jukjeon Dental Hospital. Pretreatment CBCTs for patients presenting with buccally localized unilateral maxillary impacted canines were retrospectively acquired. The contralateral normally localized maxillary canines served as controls. The institutional review board of Dankook University Jukjeon Dental Hospital approved the study under the number 2402001002. The sample comprised 31 individuals (5 male, 26 female), with ages ranging from 8 to 30 years (mean 13.52 ± 4.84 years) (Table 1). The inclusion criteria included: (1) unilateral buccally localized impaction of a maxillary canine (patients younger than the typical age for canine eruption are included if there is no change in the angle and direction of the canine even after six months of observation), and (2) availability of high-quality CBCTs capturing both the impacted and the contralateral normally localized canines. The exclusion criteria encompassed: (1) diagnosed craniofacial congenital anomalies or syndromes, (2) dental traumatic injuries, (3) the presence of adjacent anomalous or missing teeth, and (4) a history of orthodontic treatment.

Computed tomographic analysis

The CBCT images in this study were analyzed using Invivo 6 plus, version 6.5 software (Anatomage, San Jose, USA) by a single investigator (J.E.J). Variables such as rotation, angulation, torque, root

Table 1. Gender ratio and mean age of the study population

Gender (n)	Male	5 (16%)
	Female	26 (84%)
Age (Mean ± SD)		13.52 ± 4.84

SD, standard deviation.

volumes, root lengths, and the presence of hooked apices were measured. The palatal plane, defined by the horizontal line connecting both orbitales and passing through the ANS and PNS, served as the horizontal reference. The midpalatal plane, passing through the ANS and PNS and perpendicular to the palatal plane, was used as the vertical reference. A vertical plane through the ANS and perpendicular to both the palatal and midpalatal planes functioned as the transversal reference (Fig. 1).

Rotation was quantified in the axial view as the angle between a tangent to the buccal contour of the tooth and the midpalatal plane. Inclination was determined in the coronal view as the angle between the tooth's long axis and the midpalatal plane. Torque was evaluated from the sagittal view as the angle between the tooth's long axis and the palatal plane (Fig. 2). Further, the canine's root length, root volume, and the presence or absence of an apical hook were assessed. Root length was measured along the

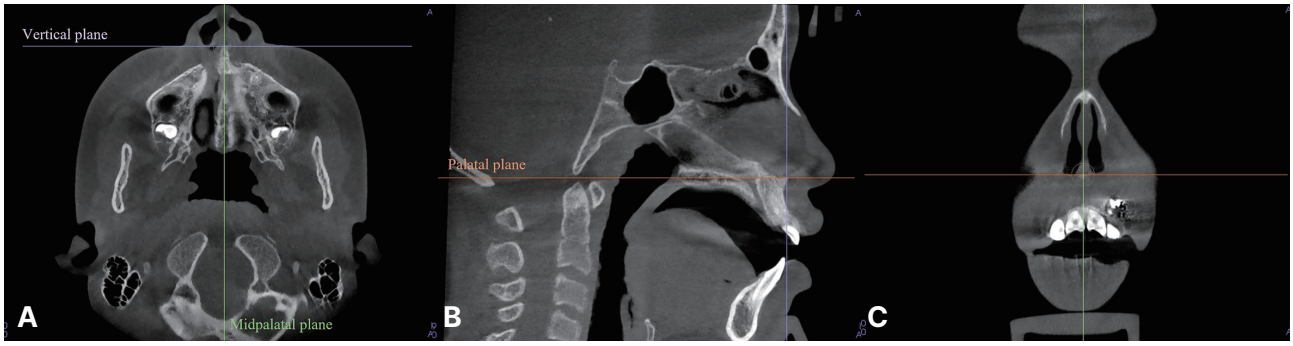

Fig. 1. Orientation of reference planes. (A) Axial view, (B) Sagittal view, (C) Coronal view.

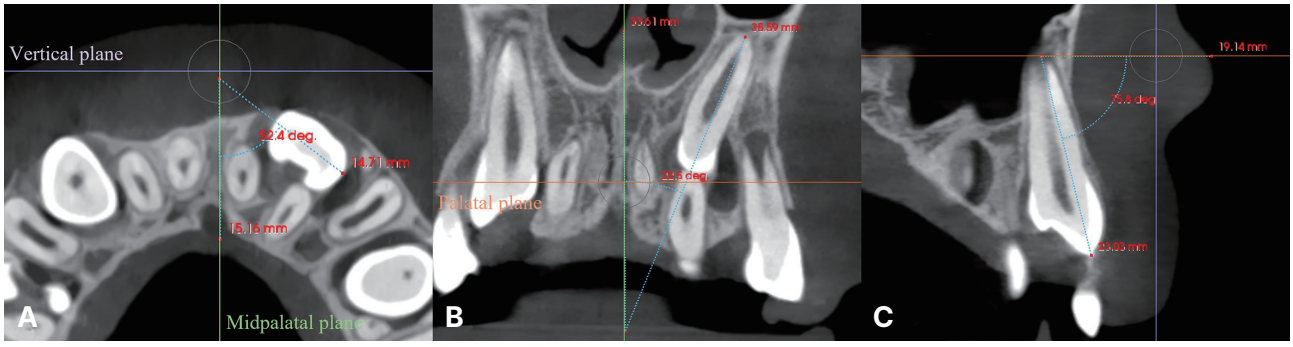

Fig. 2. Canine three-dimensional position measurements. (A) Rotation, (B) Angulation, (C) Torque.



Fig. 3. Measurement of canine root characteristics. (A) Root length, (B) Root volume, (C) Apical hook.

long axis from the canine tip to the root apex using a three-dimensional model of canine segmentation. Root volume was calculated from the volume of the entire tooth (including the crown) using a three-dimensional model of canine segmentation. An apical hook was considered present if the angulation in the apical third of the canine root exceeded 50 degrees relative to the root's long axis (Fig. 3).

Statistical analysis

All statistical analyses employed SPSS Statistics for Windows, version 25.0 (IBM Corp., Armonk, USA). Descriptive statistics calculated the mean and standard deviation for each variable. The Shapiro-Wilk test checked for normality, while the Levene test assessed homogeneity. Fisher's exact test and the Mann-Whitney U test were used to compare the gender ratio and age between groups with canine impaction and the control group, respectively. The paired-sample t-test compared dependent variables between the impacted canines and the contralateral controls.

Pearson correlation analysis was used to examine the relationship between age and differences in each variable. The intraclass correlation coefficient, evaluating the reliability of the measurements, was analyzed by re-assessing 8 randomly selected CBCT images two weeks after the initial measurements by the same investigator. A significance level of $P < 0.05$ was established for all tests.

Results

The Intraclass Correlation Coefficient evidenced high reliability across all assessed variables, ranging from 0.957 (impacted canine angulation) to 0.999 (impacted and contralateral canine apical hook).

When comparing the impacted canine (IC) with the contralateral canine (CC), all variables exhibited significant differences at except for the apical hook. The impacted canine (IC) demonstrated, on average, 17.89 degrees more mesiopalatal rotation and 16.73 degrees more mesiodistal angulation compared to the contralateral canine (CC). Regarding torque, root length, and volume, the contralateral canine (CC) presented higher values than the impacted canine (IC). The increased torque in the contralateral canine (CC) implies a more upright position. The root length of the impacted canine (IC) was notably shorter than that of the contralateral canine (CC) by an average of 1.68 mm, and the root volume was significantly lesser by an average of 48 mm^3 (Table 2).

The correlation analysis between the absolute value of the difference in variables ([IC-CC]) and age is detailed in Table 3. A significant positive correlation ($P < 0.001$) was evidenced between the differences in angulation and torque across canines, and a significant positive relationship was also observed between the differences in root length and volume ($P < 0.016$). A significant positive correlation was found between age and the difference in root length ($P < 0.004$), indicating that the disparity in root length between the

Table 2. Comparison of variables according to canine impaction

	IC	CC	Mean difference	IC/CC ratio (%)	*P* value
Rotation (º)	61.68 ± 3.42	43.79 ± 2.73	17.89 ± 3.45	140.85	< 0.001***
Angulation (º)	28.30 ± 4.07	11.57 ± 0.87	16.73 ± 4.05	244.60	< 0.001***
Torque (º)	50.81 ± 4.34	72.64 ± 1.49	-21.83 ± 4.30	69.95	< 0.001***
Root length (mm)	20.14 ± 0.37	21.81 ± 0.49	-1.68 ± 0.27	92.34	< 0.001***
Root volume (mm^3)	639.97 ± 24.47	688.67 ± 21.93	-48.70 ± 11.76	92.93	< 0.001***
Apical hook (n)	1 (0.03%)	0 (0%)	-	-	0.326

IC, Impacted canine; CC, Contralateral canine.
* $P < .05$, ** $P < .01$, *** $P < .001$.

Table 3. Correlation between age and the absolute value of the difference in variables between the impacted canine and contralateral canine

		Age	Rot [IC-CC]	Ang [IC-CC]	Tor [IC-CC]	RL [IC-CC]	RV [IC-CC]
Age	Pearson correlation	1					
	P value						
Rot [IC-CC]	Pearson correlation	0.074	1				
	P value	0.698					
Ang [IC-CC]	Pearson correlation	0.073	-0.092	1			
	P value	0.701	0.630				
Tor [IC-CC]	Pearson correlation	0.240	-0.044	0.684**	1		
	P value	0.202	0.816	0.000			
RL [IC-CC]	Pearson correlation	0.507**	0.078	0.234	0.242	1	
	P value	0.004	0.683	0.214	0.198		
RV [IC-CC]	Pearson correlation	-0.131	-0.156	0.260	0.326	0.435*	1
	P value	0.489	0.409	0.165	0.079	0.016	

IC, Impacted canine; CC, Contralateral canine; Rot, Rotation; Ang, Angulation; Tor, Torque; RL, Root length; RV, Root volume.
* $P < .05$, ** $P < .01$, *** $P < .001$.

impacted canine and the contralateral normal canine escalates with age. Nonetheless, the correlation between age and the difference in root volume did not achieve statistical significance (Table 3).

Discussion

Apart from the third molars, the maxillary canine is the tooth most frequently encountered as impacted.[3,16] Specifically, buccal impaction of the maxillary canine predominantly occurs among Asians.[17] Sajnani and King have demonstrated that impaction of the maxillary canine can be identified post the age of 8,[18] and clinically, the likelihood of canine impaction may be inferred from the presence of a labial bulge in patients aged between 9 to 10 years.[3] Impaction of the canine is known to lead to complications such as ankylosis, cystic formations, and displacement and root resorption of neighboring teeth if not timely addressed.[8,19,20] Furthermore, the maxillary canine undergoes eruption via mesial, palatal, and occlusal migration following the formation of the tooth germ.[21] If this migration process is impaired, it could hinder root development, resulting in a shortened root or root dilaceration. Consequently, the need for a predictive model to facilitate timely intervention in cases of canine impaction is evident.

This study was designed to undertake a three-dimensional comparison of impacted canines with their contralateral counterparts in patients exhibiting unilateral buccal impaction of the maxillary canine. Utilizing CBCT images, this exploration examined differences in rotation, angulation, torque, root length, root volume, and apical curvature between the left and right maxillary canines in cases of impaction. There is a scarcity of research analyzing unilateral maxillary buccal impacted canines using CBCT images and skeletal reference lines. In this work, the palatal plane was utilized as a three-dimensional skeletal reference, offering a reliable benchmark while minimizing radiation exposure for adolescent patients. In the current study, the CBCT images of maxillary impacted canines, including the palatal plane, had a field of view of 100 × 50 mm, which provides a lower radiation dose compared to the field of view required for full skull scanning that includes reference planes such as the occlusal plane. Conflicting outcomes have been reported in previous studies concerning root development in impacted canines, with research on buccally impacted canines also being limited.[1,13-15]

Earlier panoramic studies predominantly relied on

canine angulation alone as an indicator of impaction risk. Yet, the findings of this study reveal that not only canine angulation but also rotation and torque should be considered as indicators of impaction risk when using three-dimensional computer tomographic imagery. These findings align with those from prior CBCT studies.[6,11] In the impaction group (IG), it was observed that the impacted canine (IC) exhibited an average increase of 17.89 degrees in mesiopalatal rotation and an average increase of 16.73 degrees in mesiodistal angulation compared to the contralateral canine (CC). The rotation of impacted canines should be considered not only as a predictive factor for impaction but also in surgical approaches and force mechanics during forced eruption of the impacted tooth. Studies focused on the rotation of impacted canines are rare. Drawing parallels from observations on the lateral incisor, the tooth adjacent to the impacted canine, Barros et al. described a frequent mesiolabial rotation of lateral incisors in individuals at high risk of maxillary canine impaction.[22] Similarly, Chanshu et al. noted mesiolabial rotation in a patient with an impacted maxillary canine.[23] Dekel et al. reported a mean mesiobuccal rotation of 18 degrees in the lateral incisors of patients with buccally impacted maxillary canines.[1] While these studies align with the current findings, further research focusing on the canine is warranted.

Regarding root length and volume, the contralateral canine (CC) demonstrated superior values compared to the impacted canine (IC), suggesting that canine impaction influences root development. The finding that there is a difference in root length and volume between impacted canines and normal canines suggests that treatment of the impacted tooth at an appropriate time is necessary to promote root growth. This should be considered in the force mechanics during treatment and in the prognosis after treatment of the impacted tooth. Cao et al. postulated that buccally impacted maxillary canines encounter restricted space for root development owing to limited arch space.[12] Dekel et al. found a significant reduction in the root length of buccally impacted maxillary canines compared to their contralateral equivalents, by an average of 1.3 mm; however, no significant disparity in root volume was observed.[1] Leonardi et al. reported no variance in root volume between impacted canines and their contralateral teeth, yet their study was focused on palatally impacted maxillary canines.[15] No significant difference was detected in the presence of an apical hook between the impacted canine (IC) and the contralateral canine (CC), potentially due to the mean chronological age of the sample being 13.52 years, which precedes the completion of canine apex development. According to Dekel et al., albeit not statistically significant, impacted canines displayed a fourfold increase in apical hooks compared to their contralateral normal counterparts.[1] Cao et al. observed a statistically significant higher occurrence of apical hooks in impacted canines than in normal ones, attributing this to the proximity of impacted canines' roots to the maxillary sinus or nasal floor.[12] Nonetheless, the mean chronological age in these studies was greater than that in the current investigation.

A pronounced positive correlation was established between the disparity in root length between the impacted canine and the contralateral normal canine and age. This signifies that with advancing age, the discrepancy in root length between the impacted and contralateral normal canine intensifies, underscoring the impact of canine impaction on root development as shown by this study's results.

One limitation of this study is the limited number of samples included, necessitating further research with a larger sample size to develop a predictive model for buccal impaction of the maxillary canines.

Conclusion

The palatal plane can serve as a skeletal reference plane for predicting canine impaction with the advantage of a low radiation dose.

Predictors of impaction are not limited to canine angulation but also include rotation and torque.

Compared to the contralateral normally positioned canine, the unilateral buccally impacted canine exhibited an increased mesiopalatal rotation by an average of 17.89 degrees and a mesiodistal angulation by an average of 16.73 degrees.

The unilateral buccally impacted canine demonstrated a reduction in root length by an average of 1.68 mm and a decrease in root volume by an average of 48 mm^3 compared to the root of the contralateral normally localized canine.

ORCID

Eujin Jang https://orcid.org/0009-0006-7429-1033
Dong-Hwa Chung https://orcid.org/0000-0003-3633-8209
Jin-Woo Lee https://orcid.org/0000-0003-3648-090X
Sang-Min Lee https://orcid.org/0000-0003-1843-7406
Mo-Hyeon Lee https://orcid.org/0000-0001-5592-3820

References

1. Dekel E, Nucci L, Weill T, Flores-Mir C, Becker A, Perillo L, Chaushu S. Impaction of maxillary canines and its effect on the position of adjacent teeth and canine development: A cone-beam computed tomography study. Am J Orthod Dentofacial Orthop 2021;159:e135-47.
2. Kim Y, Hyun HK, Jang KT. The position of maxillary canine impactions and the influenced factors to adjacent root resorption in the Korean population. Eur J Orthod 2012;34:302-6.
3. Bedoya MM, Park JH. A review of the diagnosis and management of impacted maxillary canines. J Am Dent Assoc 2009;140:1485-93.
4. Power SM, Short MB. An investigation into the response of palatally displaced canines to the removal of deciduous canines and an assessment of factors contributing to favourable eruption. Br J Orthod 1993;20:215-23.
5. Katsnelson A, Flick WG, Susarla S, Tartakovsky JV, Miloro M. Use of panoramic x-ray to determine position of impacted maxillary canines. J Oral Maxillofac Surg 2010;68:996-1000.
6. Alqerban A, Jacobs R, Fieuws S, Willems G. Radiographic predictors for maxillary canine impaction. Am J Orthod Dentofacial Orthop 2015;147:345-54.
7. Ross G, Abu Arqub S, Mehta S, Vishwanath M, Tadinada A, Yadav S, Upadhyay M. Estimating the 3-D location of impacted maxillary canines: A CBCT-based analysis of severity of impaction. Orthod Craniofac Res 2023;26:81-90.
8. Warford JH Jr, Grandhi RK, Tira DE. Prediction of maxillary canine impaction using sectors and angular measurement. Am J Orthod Dentofacial Orthop 2003;124:651-5.
9. Bodner L, Bar-Ziv J, Becker A. Image accuracy of plain film radiography and computerized tomography in assessing morphological abnormality of impacted teeth. Am J Orthod Dentofacial Orthop 2001;120:623-8.
10. Pakbaznejad Esmaeili E, Ilo AM, Waltimo-Sirén J, Ekholm M. Minimum size and positioning of imaging field for CBCT scans of impacted maxillary canines. Clin Oral Investig 2020;24:897-905.
11. Zeno KG, Ghafari JG. Palatally impacted canines: A new 3-dimensional assessment of severity based on treatment objective. Am J Orthod Dentofacial Orthop 2018;153:387-95.
12. Cao D, Shao B, Izadikhah I, Xie L, Wu B, Li H, Yan B. Root dilaceration in maxillary impacted canines and adjacent teeth: A retrospective analysis of the difference between buccal and palatal impaction. Am J Orthod Dentofacial Orthop 2021;159:167-74.
13. Silva AC, Capistrano A, Almeida-Pedrin RR, Cardoso MA, Conti AC, Capelozza L Filho. Root length and alveolar bone level of impacted canines and adjacent teeth after orthodontic traction: a long-term evaluation. J Appl Oral Sci 2017;25:75-81.
14. Hettiarachchi PV, Olive RJ, Monsour P. Morphology of palatally impacted canines: A case-controlled cone-beam volumetric tomography study. Am J Orthod Dentofacial Orthop 2017;151:357-62.
15. Leonardi R, Muraglie S, Crimi S, Pirroni M, Musumeci G, Perrotta R. Morphology of palatally displaced canines and adjacent teeth, a 3-D evaluation from cone-beam computed tomographic images. BMC Oral Health 2018;18:156.
16. Becker A, Chaushu S. Etiology of maxillary canine impaction: a review. Am J Orthod Dentofacial Orthop 2015;148:557-67.
17. Oliver RG, Mannion JE, Robinson JM. Morphology of the maxillary lateral incisor in cases of unilat-

eral impaction of the maxillary canine. Br J Orthod 1989;16:9-16.
18. Sajnani AK, King NM. Early prediction of maxillary canine impaction from panoramic radiographs. Am J Orthod Dentofacial Orthop 2012;142:45-51.
19. Shin JH, Oh S, Kim H, Lee E, Lee SM, Ko CC, Kim YI. Prediction of maxillary canine impaction using eruption pathway and angular measurement on panoramic radiographs. Angle Orthod 2022;92: 18-26.
20. Schroder AGD, Guariza-Filho O, de Araujo CM, Ruellas AC, Tanaka OM, Porporatti AL. To what extent are impacted canines associated with root resorption of the adjacent tooth?: A systematic review with meta-analysis. J Am Dent Assoc 2018; 149:765-77.e8.
21. Yan B, Sun Z, Fields H, Wang L, Luo L. Etiologic factors for buccal and palatal maxillary canine impaction: a perspective based on cone-beam computed tomography analyses. Am J Orthod Dentofacial Orthop 2013;143:527-34.
22. Barros SE, Heck B, Chiqueto K, Ferreira E. Clinical predictors of potentially impacted canines in low-risk patients: A retrospective study in mixed dentition. Korean J Orthod 2023;53:106-15.
23. Chaushu S, Vryonidou M, Becker A, Leibovich A, Dekel E, Dykstein N, Nucci L, Perillo L. The labiopalatal impacted canine: Accurate diagnosis based on the position and size of adjacent teeth: A cone-beam computed tomography study. Am J Orthod Dentofacial Orthop 2023;163:690-9.

편측성 협측 매복 상악 견치의 3차원 분석

장유진 전공의, **정동화*** 교수, **이진우** 교수, **이상민** 교수, **이모현** 교수
단국대학교 치과대학 치과교정학교실

목적: 본 연구의 목적은 구개평면을 기준 평면으로 하여 편측 상악 견치 협측 매복 환자에서 매복 견치를 3차원적으로 반대측 정상 견치와 비교하는 것이다.
연구 재료 및 방법: 편측성 상악 견치 협측 매복으로 진단된 총 31명의 컴퓨터단층영상을 수집하여 매복 견치와 반대측 정상 견치를 비교하였다. Rotation, torque, angulation, root length, root volume의 변수에 대해 각각 분석하였고, 각 변수에 대한 양측 견치의 결과값의 차이와 연령과의 상관관계를 확인하였다.
결과: 매복 견치와 반대측 정상 견치 간 rotation, angulation, torque, 치근 길이, 치근 부피에서 유의차를 보였다. 매복 견치와 반대측 정상 견치 간 치근 길이 차이와 연령 간에는 유의한 양의 상관관계가 존재하였다.
결론: 상악 견치 매복 예측에 구개평면이 골격성 기준평면으로 이용될 수 있으며, 매복의 예측 인자로 rotation, angulation, torque가 이용될 수 있다. 편측 협측 매복된 상악 견치는 반대측 정상 견치보다 유의하게 짧은 치근 길이 및 작은 치근 부피를 보였다.

(구강회복응용과학지 2024;40(4):225-33)

주요어: 삼차원; 영상; 매복; 치아

*교신저자: 정동화
(16890)경기도 용인시 수지구 죽전로 152 단국대학교 치과대학 죽전치과병원 치과교정과
Tel: 031-260-5700 | Fax: 031-548-1071 | E-mail: orthoforum@gmail.com
접수일: 2024년 8월 21일 | 수정일: 2024년 9월 23일 | 채택일: 2024년 10월 8일