https://doi.org/10.14368/jdras.2025.41.1.46
ISSN 2384-4353 eISSN 2384-4272

Case Report

Complete denture and implant-supported overdenture restoration focusing on occlusal improvement using digital occlusion analysis: a case report

Ga-Hyun Lee, Young-Eun Cho, Young-Gyun Song*
Department of Prosthodontics, School of Dentistry, Dankook University, Cheonan, Republic of Korea

Edentulous patients with complete dentures commonly experience loss of masticatory force due to the wear of the prostheses. The presence of premature contacts and uneven bilateral balanced occlusion disturbs denture stability, resulting in difficulties with continuous denture use. The conventional qualitative occlusal analysis had its limitations, as it only subjectively compared the contact points and density. To compensate for the limitation, a quantitative method using digital occlusal analyzers can offer further information on the kinetic occlusion of the prosthesis. In these two clinical cases, digital occlusal analyzers were facilitated to analyze intercuspal relationships in the complete dentures and mandibular overdentures for quantitative analysis. This approach was practical for identifying the occlusal defects of the current dentures, evaluation of the mid-treatment process, and beneficial for establishing the bilateral balanced occlusion. However, the technical limitations of the digital occlusal analyzer should be acknowledged, such as potential film damage and reduced measurement accuracy with multiple uses. **(J Dent Rehabil Appl Sci 2025;41(1):46-58)**

Key words: balanced dental occlusion; complete denture; implant-supported denture

Introduction

Gradual denture wear among edentulous patients is influenced by factors such as abrasion, chemical disintegration, and surface fatigue of artificial teeth and resin bases. Wear depends on intraoral conditions such as neuromuscular forces, salivary flow, pH, exposure to abrasive or corrosive atmosphere, patient habits, diet, poor or excessive oral hygiene, and the type of restorative material used.[1]

In full mouth restoration with complete dentures, the concept of bilateral balanced occlusion (BBO) established by Gysi in 1910, is recognized as beneficial.[2] The Glossary of Prosthodontic Terms states the "bilateral balanced articulation" or "balanced articulation" as "the bilateral, simultaneous posterior occlusal contact of teeth in maximal intercuspal position and eccentric positions".[3] The BBO offers stability and comfort to the dentures due to its well-distributed contacts, provides simultaneous contacts during eccentric excursion movements, and promotes better masticatory efficiency.[4] The necessity of 'balanced occlusion', achieved by providing the most possible supporting area, promotes denture retention and stability thereby extending denture longevity.[5]

Premature contact contributes to the failure of the bilateral balanced occlusion, denture instability, reduced masticatory efficiency, and damage to the mastication system. Undistributed occlusal forces can destabilize complete denture prostheses dur-

*Correspondence to: Young-Gyun Song
Professor, Department of Prosthodontics, College of Dentistry, Dankook University, 119, Dandae-ro, Dongnam-gu, Cheonan, 31116, Republic of Korea
Tel:+82-41-550-1932, Fax: +82-41-550-0256, E-mail: ygsong@dankook.ac.kr
Received: October 10, 2024/Last Revision: October 29, 2024/Accepted: November 13, 2024

Copyright© 2025 The Korean Academy of Stomatognathic Function and Occlusion.
©It is identical to Creative Commons Non-Commercial License.

ing the mastication and jaw movements, resulting in the dislodgment of both upper and lower opposing complete dentures.[6] Previous studies have shown that mastication efficiency can decrease by up to 20% in bite force when malocclusion is present.[7] Excessive force, even when limited to certain premature contact points and exceeding just a few microns, can cause temporomandibular joint pain and myalgia.[8]

To evaluate the occlusal relationships of the prostheses, both qualitative and quantitative occlusal analysis methods can be considered.[8] The qualitative method, commonly used at the chairside, relies on conventional static occlusal indicators to identify intercuspal contact areas and subjectively detect heavy contact points in the occlusion.[9]

Two of the static occlusal recording materials mainly used in the qualitative method are articulating paper and shim stock. The articulating paper detects relatively high intercuspal contacts by the width and intensity of recorded ink marks in the intraoral conditions. Its credibility is questioned when the possibility of pseudo marks of premature contacts and is premature contact occlusal evaluation, lacking the correlation between mark size and bite force load, which may be influenced by saliva.[10] The Metallic Shimstock film (Bausch Arti-Fol, Bausch articulating paper Inc., Nashua, USA) is a 12-micron-thick polyester film which is used to detect "withdrawal resistance" that supposedly indicates subjective levels of forceful or non-forceful occlusal contacts.[9]

Limitations exist within the qualitative occlusal analysis. The localization of the occlusal contact points can be determined but neither the sequence nor density of the contacts can be measured.[11] The quantitative occlusal analysis method, along with the quantifiable occlusal indicators, was accommodated to overcome the limitations and subjectivity of the static centric occlusion indicators.[9] In the same context, the concept of bilateral balanced occlusion introduced by Gysi was originally developed on an articulator with symmetrical fixed rotation centers, which does not account for the contact points during the mid-kinetic movement of the mandible, nor for the variations in complex temporomandibular anatomy.[5]

The quantitative method of occlusal evaluation can provide additional information on the relative occlusal contact force levels per tooth, the density of the contacts, and the sequence of the contacts during the mandibular masticatory movements.[11] Two of the quantifiable occlusal indicators were used: T-Scan Novus (Tekscan Inc., S. Boston, USA) and Dental Prescale II (Fuji Film Co., Tokyo, Japan).

The T-Scan Novus is an electro-optic, piezoelectric, and resistive system that records patients' occlusion, and is one of the most researched quantifiable systems for determining occlusal relationships.[9] It utilizes a U-shaped, 60-micron-thick sensor foil with in-between conductive ink. In this system, the patient occludes into the maximum intercuspal position (MIP), and electrical resistance develops at occluding points as particles are physically brought closer, diminishing the electrical resistance, and records the occlusion pattern and sequence.[8,11] This computerized system can therefore directly determine premature high points, regions of excessive force, and non-uniform force concentration.[11,12] The data can be stored digitally for analysis in a time-based video format.[12] The film is subject to elastic deformation.[7]

The Dental Prescale system is a photo-occlusion technique that analyzes maximum bite force (N), occlusal contact area (mm^2), and bite pressure (MPa).[9] The Prescale film is a 98 μm (approximately 0.1 mm) thick, pressure-sensitive, U-shaped sheet. The patient occludes into this single film sheet once for 10 seconds. The film is embedded with matrix-colored microcapsules coated with polyethylene-terephthalate (PTE) resin and filled with color-producing ingredients.[9] The recorded sheet is scanned using a companion color image scanner analyzer (Occluzer FPD703; GC Corp., Tokyo, Japan). The colored areas of the film are then inspected under polariscope light within the Occluzer FPD703 to determine the relative intensities of occlusal force at different tooth contact points.[9]

In upcoming clinical cases for restoration of edentulous patients, occlusal rehabilitation was primarily based on quantitative occlusion analysis, acquired by the digital occlusal analyzers; the T-Scan Novus and Prescale devices. The analysis was integrated into the

diagnosis process, as well as before, throughout, and after the delivery.

Case Reports

Case 1

A 77-year-old male patient with a fair edentulous ridge has presented to the clinic with old ill-fitting complete dentures (Fig. 1). Regarding the old denture, the patient reported decreased efficiency in food mastication and hoped for aesthetic improvement noting that the current maxillary anterior teeth appeared too short, giving the impression of being hidden beneath the upper lip during speech or smiling. Additionally, the patient mentioned his visual impairment as a notable medical condition (Fig. 2).

The old denture was evaluated by the clinician in aspects of function, stability, and adequacy in portraying a reasonable occlusion vertical dimension (OVD). The old prostheses were fabricated a year ago and maintained a good fit to the alveolar ridge due to the patient's regular clinic visits. The settings of the occlusal plan and occlusal vertical dimension were adequate. The patient's temporomandibular complex was well adjusted, with no reported concerns. Therefore, these validations were used as referenceable points for the future denture. According to the chief complaint, esthetic issues were assessed, and modification of the anterior teeth arrangements was required. Functionally, an uneven distribution of left and right masticatory forces was detected with the conventional articulating paper and Shimstock film. Further occlusion analysis was conducted by

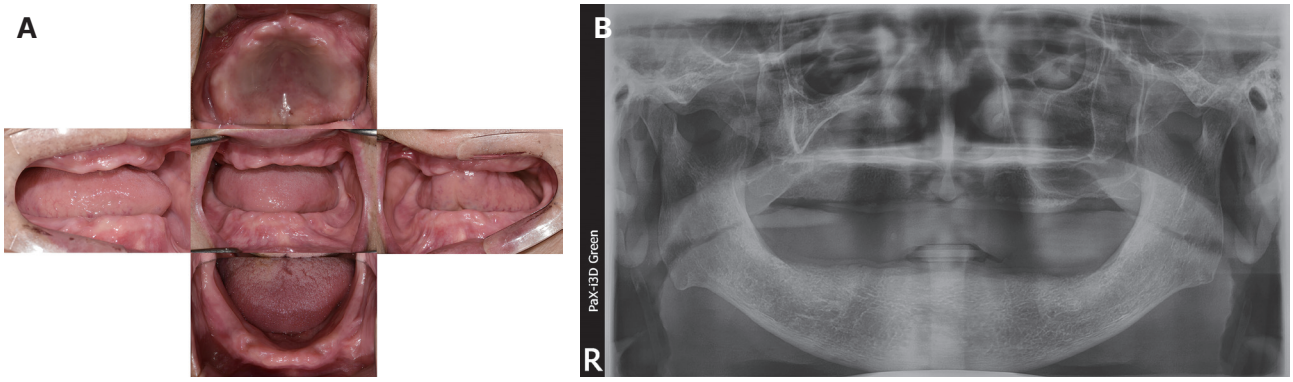

Fig. 1. Examination of patient 1 on the first visit. (A) Intraoral photos of the edentulous arch, (B) Panoramic radiograph of the patient 1.

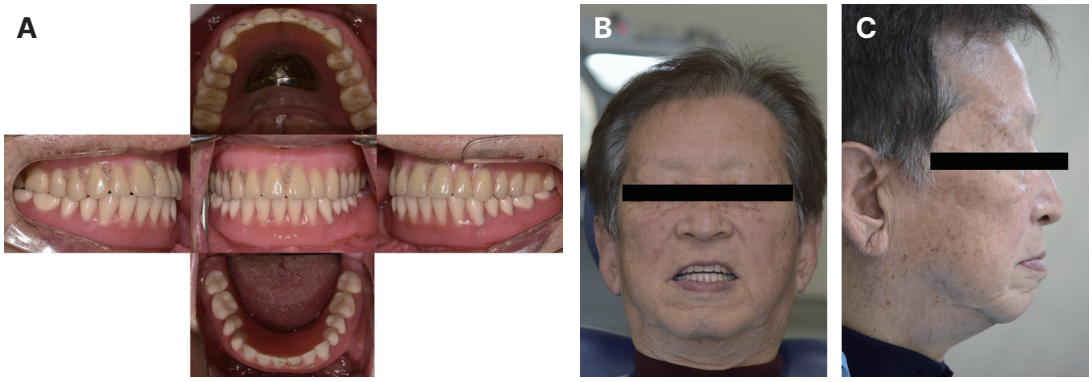

Fig. 2. Intraoral and Extraoral facial profiles of patient 1 with old dentures. (A) Intraoral photo of patient 1 with old dentures, (B) Facial profile of the patient with old dentures, (C) In the sagittal profile photo, the mandibular protrusion is observed upon closure, along with a lack of volume and support in the upper lip.

T-Scan Novus which included functional occlusal analysis of centric occlusion and lateral excursion. Premature contacts were identified as distinct columns in pink or orange. The old denture contained the right-side dominant mastication pattern. Edentulous patients experience reduced force transmission through cortical and trabecular bones due to missing dentition, resulting in lower bite force compared to dentate patients.[7] According to Atlas et al., the bite force levels may be correlated with the patient's age and sex, and the average bite force varies between 50 to 2,000 N.[7] The total bite force of patient 1 was recorded to be 64.4 N, which is located on the lower side of the average spectrum (Fig. 3).

Identical occlusal analysis was performed after the soft-reliner was applied to both the old maxillary and mandibular dentures. A slight improvement in the occlusal force and distribution was observed, but the ill-distributed pattern of occlusal contact points remained (Fig. 4). As a treatment plan, an improved-fit prosthesis was designed to better distribute inter-occlusal contact points and consequently accommodate an increase in total bite force, and the dentures were fabricated conventionally (Fig. 5).

The evaluation of the wax denture suggested that more force was distributed to the left during centric occlusion and lateral excursion (Fig. 6). Premature contact at the anterior teeth was detected and subsequently addressed, then adjusted to distribute bite force to the posterior molar area. Afterward, the wax dentures were flasked.

The occlusal evaluation of the final denture was

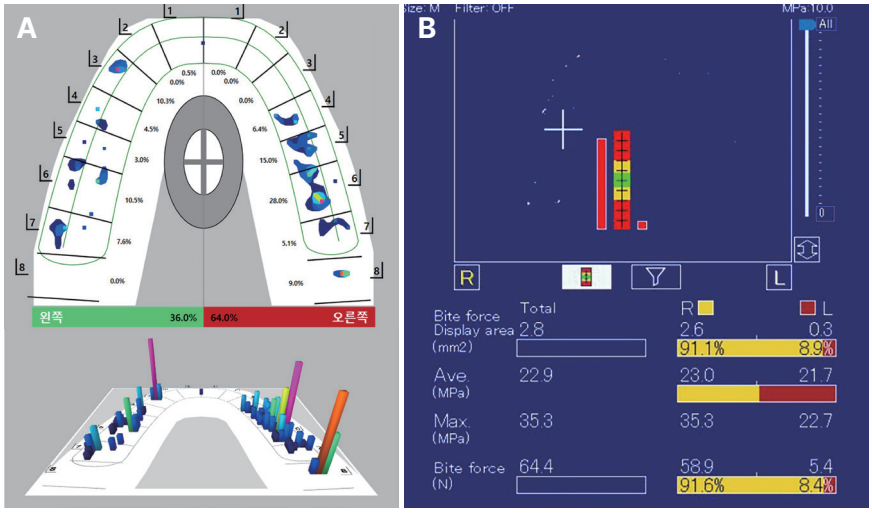

Fig. 3. The digital occlusal analysis results of the old dentures. (A) Qualitative occlusal analysis of T-Scan Novus, (B) Dental Prescale II.

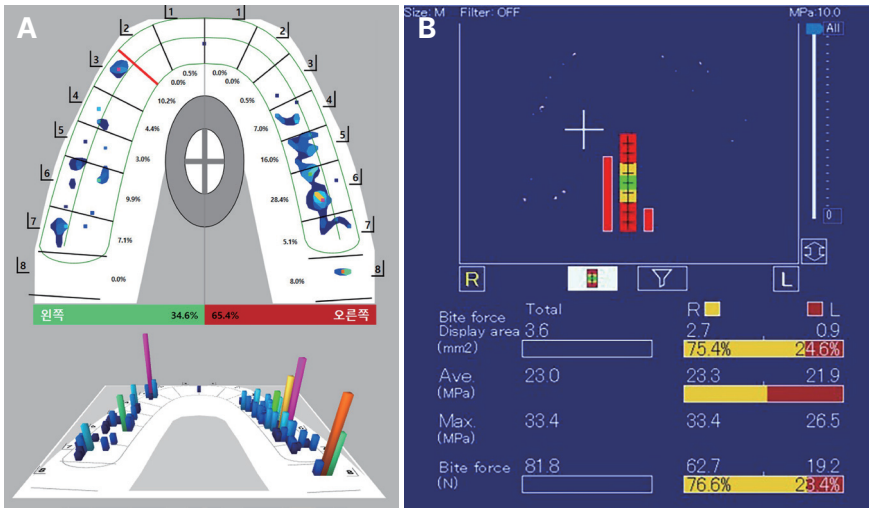

Fig. 4. The digital occlusal analysis results of the old dentures with soft-reliner tissue conditioner II (Shofu Inc., Kyoto, Japan). (A) Qualitative occlusal analysis of T-Scan Novus, (B) Dental Prescale II.

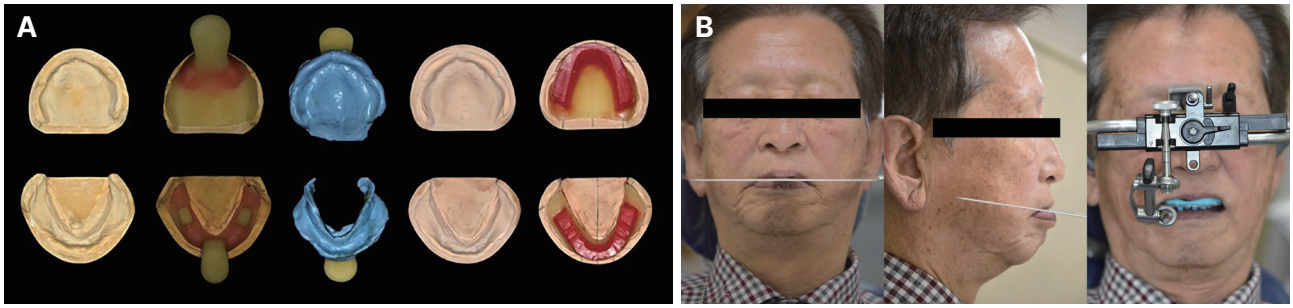

Fig. 5. The denture fabrication process of patient 1. (A) The conventional method of denture fabrication by utilizing a diagnostic cast, individual tray, master cast, and wax rim base, (B) Establishing the occlusal plane of patient 1 by using the fox's bite plan and following facebow transfer.

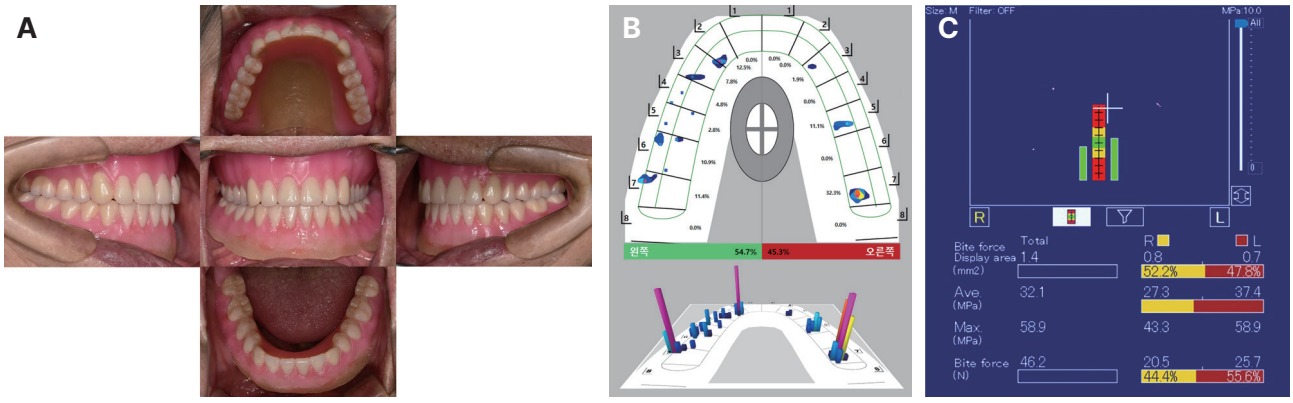

Fig. 6. Wax denture evaluation. (A) Intraoral photo of patient 1 at denture try-in, (B, C) The digital occlusal analysis of the wax denture.

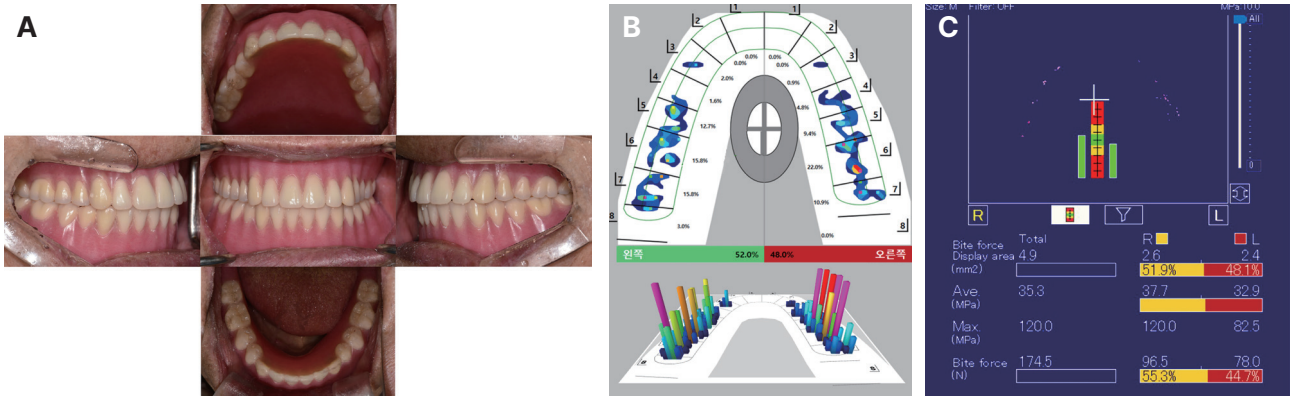

Fig. 7. Final denture evaluation. (A) Intraoral photos of patient 1 after the final denture delivery, (B, C) The digital occlusal analysis of the final denture on the 2-week recall.

conducted during the 2-week recall after delivery, allowing the patient 2 weeks to adapt to the new complete dentures, as suggested by Dapprich and Oidtman.[13] The total bite force measured by Prescale increased from 64.4 N with the old denture to 174.5 N. The right-side bite force distribution showed improvement according to the T-Scan Novus data (Fig. 7). Increased intercuspal contact points, improved denture stability, and an expended occluding area were observed, achieving bilateral balanced occlusion.

Case 2

A 68-year-old male patient reported poor fitting of the old maxillary complete dentures and implant-supported mandibular overdenture, along with a loss of masticatory efficiency. This patient exhibited asymmetrical alveolar bone resorption on the left lower and right upper alveolar arches (Fig. 8). The old mandibular implant-supported denture was fabricated seven years ago and exhibited yellowish discoloration of the artificial teeth, and the maxillary complete denture was replaced two years ago due to a fracture. The old prostheses presented some acceptable clinical aspects, along with potential modifications. The two mandibular implants remained intact, contributing to the retention and stability of the current denture. The temporomandibular complex was in equilibrium with the current occlusal vertical dimension. The old dentures maintained a good fit to the alveolar ridges during the centric occlusion; however, the upper denture showed a visible decrease in stability during the lateral movement. The occlusal plane of the old dentures was horizontally deviated to the left to align with the uneven anatomical features of alveolar ridge (Fig. 9). A lack of posterior molar contact points and force distribution was noted using the conventional articulating paper and Shimstock film. Additionally, digital analysis suggested insufficient contact area on the left posterior side, with premature contacts detected on the right side during centric occlusion, as recorded by T-Scan Novus (Fig. 10).

With the soft-reliner applied to the old maxillary denture, the total bite force of Prescale increased from 140.9 N to 155.8 N, enhancing retention and

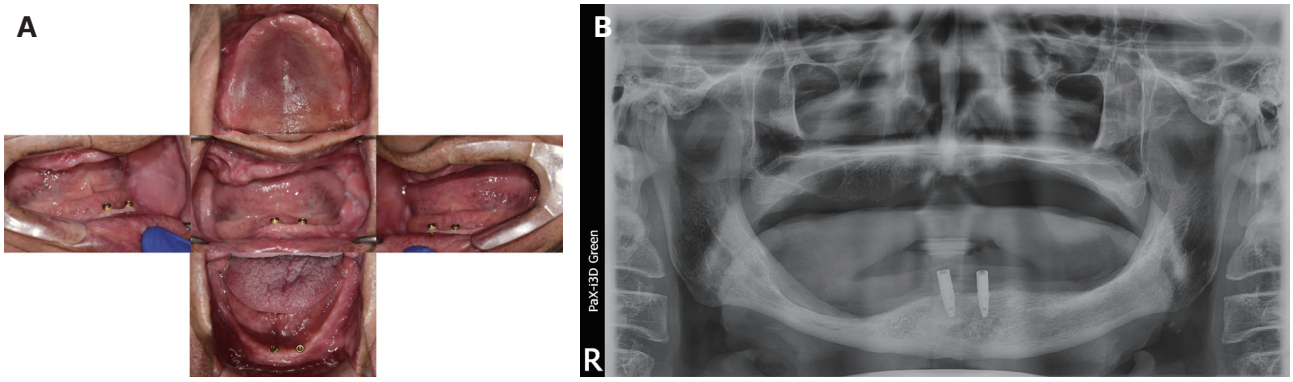

Fig. 8. Examination of patient 2 on the first visit. (A) Intraoral photos of the edentulous arch, (B) Panoramic radiograph of patient 2.

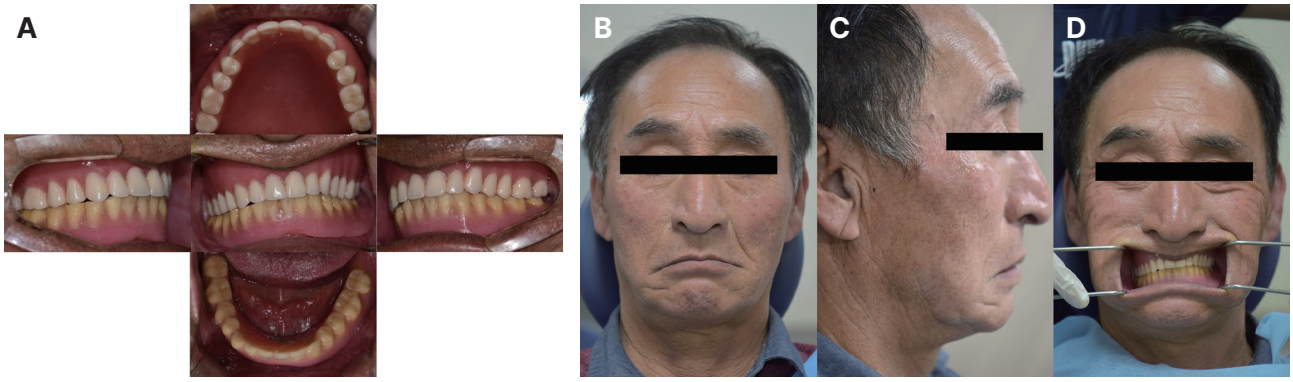

Fig. 9. Intraoral and extraoral facial profiles of patient 2. (A) Intraoral photos of patient 2 with old dentures, (B) Facial profile photo of the patient with old dentures, (C) The sagittal profile photo of patient 2, (D) Patient 2 with old dentures presenting a deviated occlusal plane.

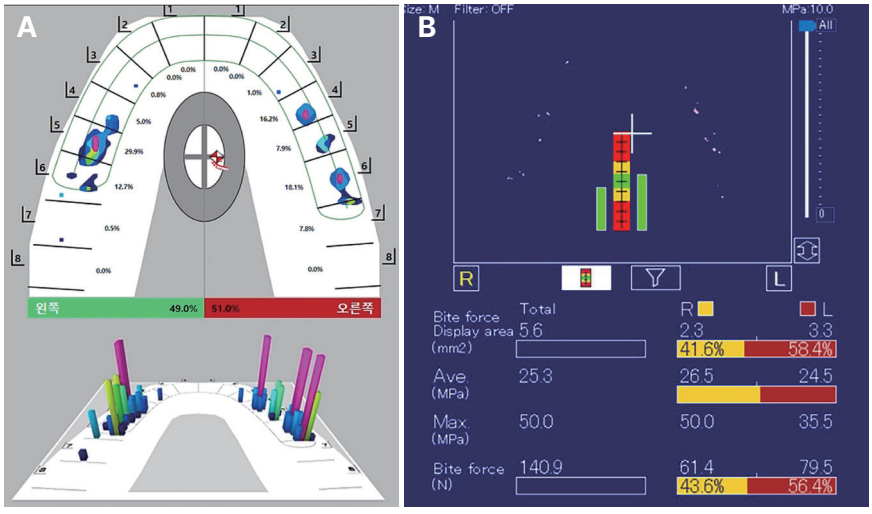

Fig. 10. The digital occlusal analysis results of the old dentures. (A) Qualitative occlusal analysis of T-Scan Novus, (B) Dental Prescale II.

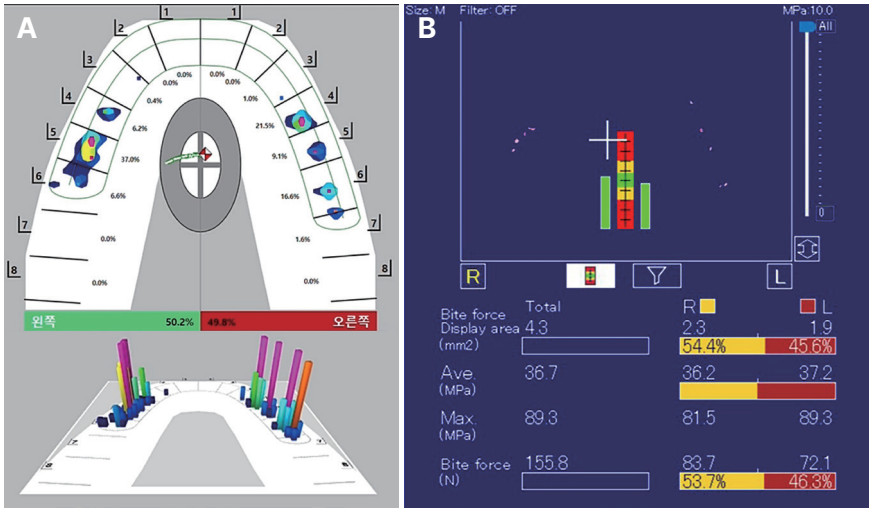

Fig. 11. The digital occlusal analysis results of the old dentures with soft-reliner tissue conditioner II (Shofu, Japan). (A) Qualitative occlusal analysis of T-Scan Novus, (B) Dental Prescale II.

stability of initially ill-fitting dentures (Fig. 11).

The quantitative occlusal measurement of the wax denture provided detailed information on premature contacts and a comparison of relative contact forces in the premolar area of Patient 2. The identical laboratory procedure for wax denture fabrication was performed as for Patient 2 (Fig. 12). By integrating the occlusal analysis of the wax denture, the premolar contact was reduced, and the contact surfaces were extended to the adjacent posterior molar area prior to the following flasking procedure of the wax dentures (Fig. 13).

The maximum bite force of the final denture increased greatly compared to the old denture, rising from 104.9 N to 209.4 N (Fig. 14). In comparison to the previous clinical case of patient 1, the posterior molar forces were weakly detected, with more occluding forces concentrated in the premolar area due to additional support from the existing mandibular implants.

Discussion

This case report highlights the clinical significance of the digital quantitative occlusal analysis in conjunction with conventional quantitative occlusal recording for complete denture restoration, from both procedural and outcome perspectives. These analyses were conducted alongside standard complete denture fabrication, with a detailed focus on occlusion adjustments. Integrating digital occlusion analysis devices into these clinical cases enabled clinicians to accurately identify occlusion problems, and assess each occluding contact and sequence, shortening the di-

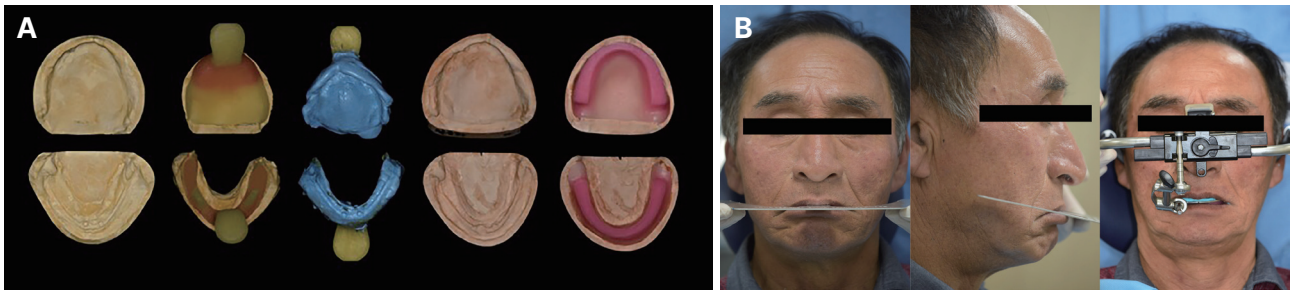

Fig. 12. Complete denture fabrication process of patient 2. (A) Conventional method of denture fabrication by utilizing a diagnostic cast, individual tray, master cast, and the wax rim base, (B) Establishing the occlusal plane for patient 1 by using the fox's bite plan and following face bow transfer.

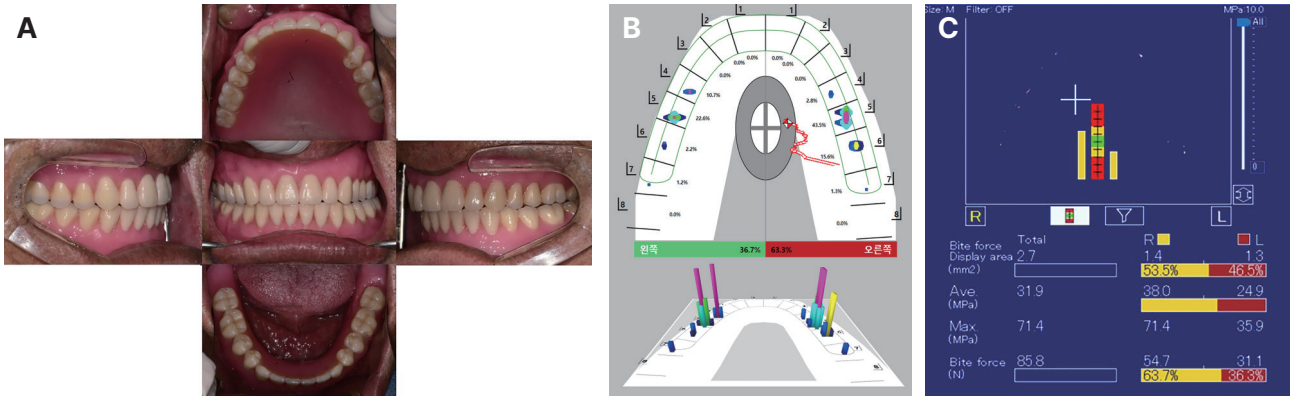

Fig. 13. Wax denture evaluation. (A) Intraoral photo of patient 2 at denture try-in, (B, C) The digital occlusal analysis of the wax denture.

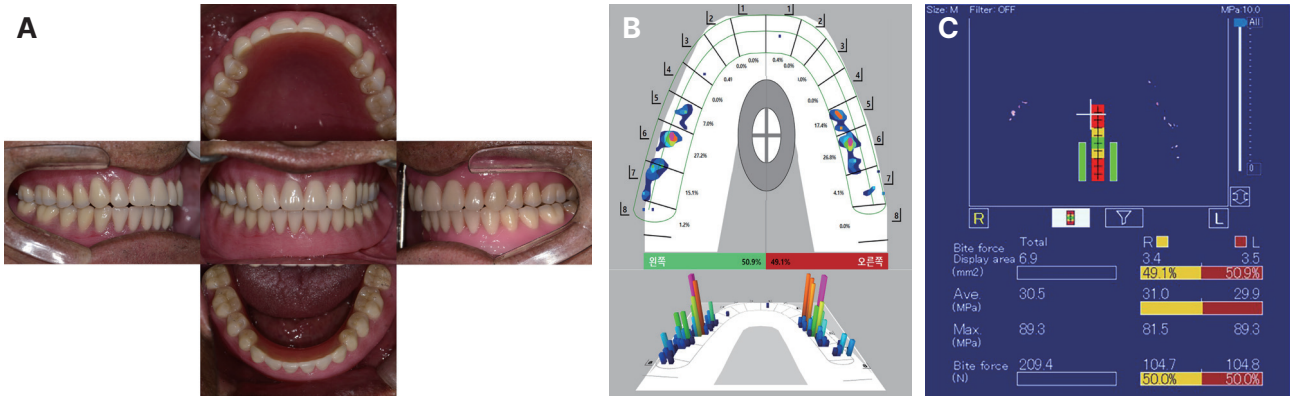

Fig. 14. Final denture evaluation. (A) Intraoral photos of the patient after the final denture delivery, (B, C) The digital occlusal analysis of the final denture on the 2-week recall.

agnostic process. Conventional quantitative occlusal recording methods only provide subjective measure of the tug and pull force at each intercuspal contact, making it challenging for clinicians to quantify the patients' total bite force. In contrast, digital devices for quantitative analysis can generate a numerical measurement of the total bite force through a single mandibular disclosure.

In Case 1, digital occlusion analysis facilitated the precise and time-efficient identification of problematic occlusion patterns during kinetic masticatory movements. In Case 2, it allowed for a more accurate

assessment of the denture's occlusal condition during dynamic movement in a complex edentulous case with irregular bone resorption and a deviated occlusal plane.

Due to the ability of digital analyzers to quantify masticatory force measurements, a comprehensive comparison of force variations within the alveolar arch and values across clinical cases has become possible. Both patients exhibited a similar trend of improvement in masticatory force values throughout the complete denture restoration procedure. The total bite force measured by Prescale tended to show an increase when the soft-liner was applied (Fig. 15, 16). The results supported the idea of the application of soft-liners distributes occlusal forces uniformly, reducing localized pressure points and improving occlusal contact across the denture-bearing area.[10] Wax dentures in both cases demonstrated a notable decrease in bite force accompanied by premature contact (Fig. 17, 18). Although the occlusion analysis

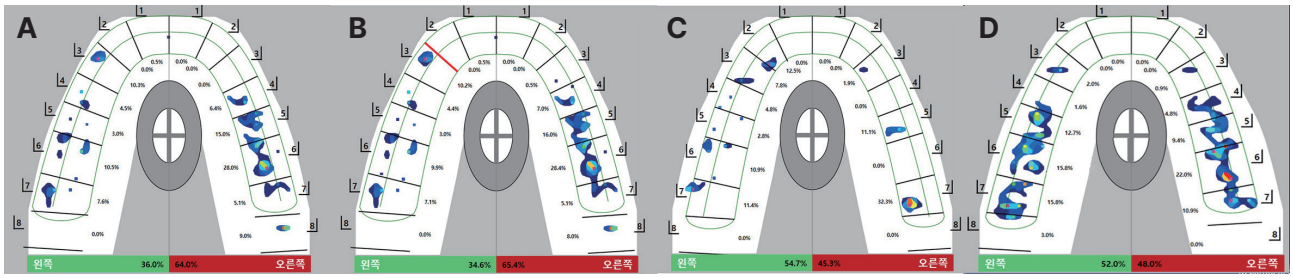

Fig. 15. T-Scan Novus analysis data at centric occlusion of patient 1. (A) Old denture, (B) old denture with soft-reliner, (C) wax denture, (D) final denture.

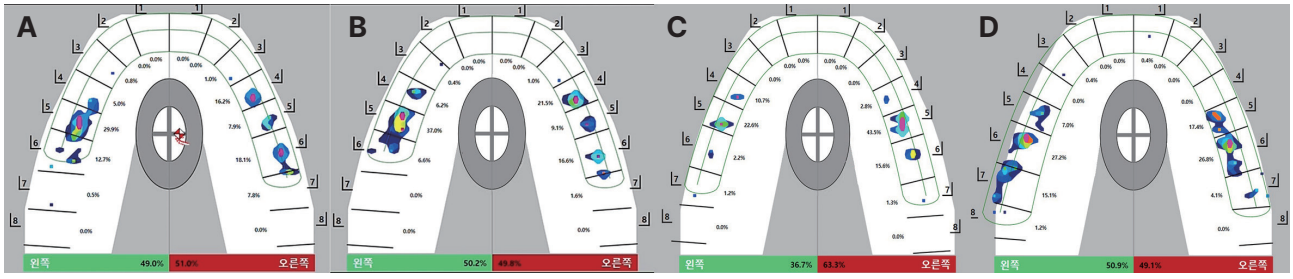

Fig. 16. T-Scan Novus analysis data at centric occlusion of patient 2. (A) Old denture, (B) old denture with soft-reliner, (C) wax denture, (D) final denture.

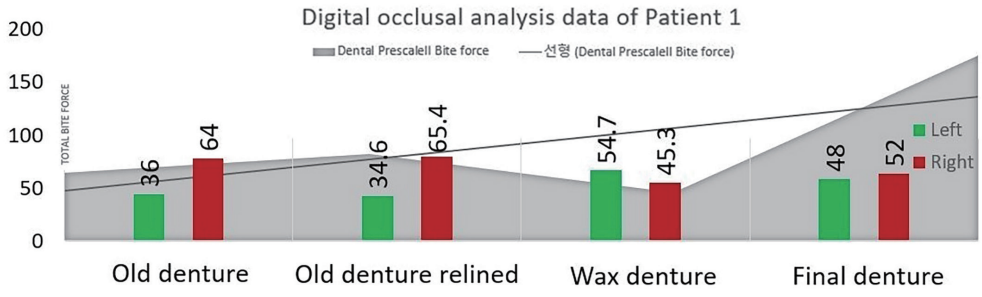

Fig. 17. Time-sequential digital occlusal analysis results of patient 1 during the treatment procedure. The total bite force graph measured by Dental Prescale II is shown in gray; left and right balance percentages from the T-Scan Novus data are displayed in green and red columns.

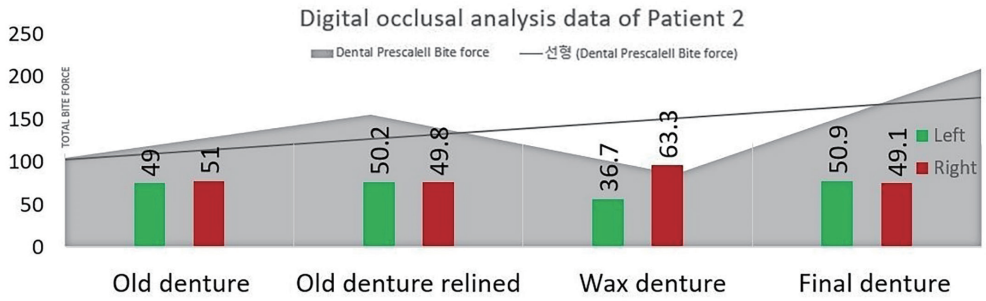

Fig. 18. Time-sequential digital occlusal analysis results of patient 2 during the treatment procedure. The total bite force graph measured by Dental Prescale II is shown in gray; left and right balance percentages from the T-Scan Novus data are displayed in green and red columns.

process was practical and beneficial in pinpointing the relative strength and location of the premature contact during the teeth arrangement evaluation of the wax denture, this case report did not consider the differences between pre- and post-wax denture flasking occlusion results, leading the findings to fall short of providing a comprehensive understanding.

One difference noted in patient 2 is that the mandibular overdenture displayed a persistent premolar-centered bite in the final denture, which implies a need for additional occlusal distribution to the posterior molars and necessitates careful follow-up for further occlusal adjustments (Fig. 17). Previous literature has described the tendency for tooth wear in mandibular overdentures, evidently in the first molars, followed by the bicuspids, due to the location of the mandibular hinge axis being closer to the posterior areas, which increases the applied force.[1] A systematic review supported improved chewing efficiency, increased maximum bite force, and enhanced patient satisfaction with mandibular implant overdentures.[7]

In detail, the T-Scan Novus was beneficial for measurably adjusting a bilaterally balanced force distribution between the left and right arch halves, offering real-time progression monitoring.[13] From a clinical perspective, the application of these analyses enhanced the complete denture restoration process with greater accuracy and confidence, distinct diagnostic screening, and cautious observation to prevent any possible temporomandibular disorder.[12] The quantitative occlusal analysis enabled an in-depth clinical examination of occlusion to achieve bilateral balanced occlusion clinically. Even if the desired occlusal scheme is not bilateral balanced occlusion, the functional occlusal analysis of these devices still contributes to establishing the occlusion of the bilateral balanced occlusion and feasibly other schemes as well.[14] Quantitative and dynamic analysis of occlusion can be a beneficial tool in denate prostheses, as well as in fixed prostheses.

However, digital devices still hold controversy regarding possible technical errors or reliability in precision and accuracy.[12] The U-shaped sensor foil of T-Scan Novus loses accuracy within the same occluding area due to its 60-micron-thick film sheet, showing fewer contacts compared to conventional methods with thinner articulating papers. Additionally, the multiple usages of the sensors show a decrease in sensor sensitivity, especially when used more than once.[9] Also, several researchers have suggested that the sensors do not have the same accuracy among themselves.[8] During the occlusion recording, there is a possibility of the sensors being damaged when forces are concentrated on a small areas, such as sharp tooth cusps.[12] For the Dental Prescale, some expressed concerns regarding the duration of compression time and factors related to patients' masticatory force during the occlusion are sorted into negligible effects on the color formation of the Prescale measurements. The reported limitations of the Dental Prescale system are attributed to the thickness and rigidity of the inflexible pressure-sensitive sheet, which can lead to over-detection of occlusal contact

areas and bite forces in the posterior teeth, with diminishing accuracy toward the anterior region.

The reliability of digital occlusal analyzers is also a concern. The T-Scan Novus is known to be the first and most widely used digital occlusal analyzer with the most accumulated data.[15] Some studies support the reliability, repeatability, and precision of the T-Scan Novus over other devices. However, the accumulated studies on the reliability of T-Scan Novus were based on laboratory conditions. Further studies could be conducted regarding the reliability and precision of T-Scan Novus or other analyzers with retrospective studies that reflect in vivo data, or literature reviews on clinical usage. Dental Prescale System can function as a quantitative occlusal analysis device; however, its 2-step procedure requires additional time for scanning and analysis. As a result, the real-time sequence of occlusal contacts cannot be observed.[16]

Additionally, for digital devices, error-occurring conditions in the occlusion measurements should be taken into consideration, to reduce the possible pseudo-recording errors. Occlusal contact records are greatly influenced by various factors, including the thickness, strength, and elasticity of the recording materials, as well as the oral environment and clinician's interpretation.[8] It has been observed that, regardless of the recording materials used, contact mark records are better portrayed when the teeth are dry, indicating that intraoral moisture primarily interferes with the recording.[8] As previous studies have suggested, the digital occlusal data for these clinical cases were obtained after drying the occluding surface of the teeth with the 3-way syringe on the dental chair unit for 15 - 20 seconds until the glistening surface disappeared. Sensors were used only once per recording.[8] Also the digital devices were tested before function by applying gentle pressure on the sensor sheet with two clenched fingers. Careful consideration of error-prone factors prior to clinical use is recommended for successful occlusal analysis

Conclusion

This clinical report outlines the rehabilitation of occlusion in edentulous patients who were previously using complete dentures. Occlusal discrepancies were identified through the application of digital occlusal analyzers and quantitative methods, and subsequent occlusal adjustments were made and systematically verified throughout the complete denture treatment protocol.

The integration of quantitative and dynamic occlusal data in complete denture treatment enabled clinicians to identify initial occlusal issues, thereby facilitating the establishment of occlusal goals and the precise adjustment of the occlusion throughout the treatment process. This approach ultimately helped clinicians conclude the treatment with confidence, ensuring the achievement of a well-distributed bilateral occlusion.

Although drawbacks exist with occlusal materials and digital devices. Clinicians must acknowledge the technical limitations of the film sensors, the error-prone environment of intraoral conditions, and the reliability and precision spectrum of the analyzers.

ORCID

Ga-Hyun Lee https://orcid.org/0009-0009-0726-0183
Young-Eun Cho https://orcid.org/0000-0003-0341-2150
Young-Gyun Song https://orcid.org/0000-0003-3789-9585

References

1. Lindquist TJ, Ogle RE, Davis EL. Twelve-month results of a clinical wear study of three artificial tooth materials. J Prosthet Dent 1995;74:156-61.
2. Abduo J, Tennant M. Impact of lateral occlusion schemes: A systematic review. J Prosthet Dent 2015;114:193-204.
3. Layton DM, Morgano SM, Muller F, Kelly JA, Nguyen CT, Scherrer SS, Salinas TJ, Shah KC, Att W, Frelich MA, Ferro KJ. Glossary of Prosthodontic Terms 2023, 10th ed. J Prosthet Dent 2023;130: e1-126.
4. Borges MHR, Miranda LFB, Dini C, Marañón-Vásquez GA, Magno MB, Maia LC, Barão VA. Clinical performance of and patient satisfaction with conventional complete dentures with different

occlusal schemes: A systematic review of systematic reviews. J Prosthet Dent 2023;130:341-50.
5. Kurth LE. Balanced occlusion. J Prosthet Dent 1954;4:150-67.
6. Kerstein RB, Thumati P, Padmaja S. Force Finishing and Centering to Balance a Removable Complete Denture Prosthesis Using the T-Scan III Computerized Occlusal Analysis System. J Indian Prosthodont Soc 2013;13:184-8.
7. Atlas AM, Behrooz E, Barzilay I. Can bite-force measurement play a role in dental treatment planning, clinical trials, and survival outcomes? A literature review and clinical recommendations. Quintessence Int 2022;53:632-42.
8. Sharma A, Rahul GR, Poduval ST, Shetty K, Gupta B, Rajora V. History of materials used for recording static and dynamic occlusal contact marks: a literature review. J Clin Exp Dent 2013;5:e48-53.
9. Qadeer S, Özcan M, Edelhoff D, Van Pelt H. Accuracy, Reliability and Clinical Implications of Static Compared to Quantifiable Occlusal Indicators. Eur J Prosthodont Restor Dent 2021;29:130-41.
10. Ibraheem EM, ElGabry HS. Effect of mandibular complete dentures relining on occlusal force distribution using T-scan system. Bull Nat Res Centr 2021;45:93.
11. Saraçoğlu A, Ozpinar B. In vivo and in vitro evaluation of occlusal indicator sensitivity. J Prosthet Dent 2002;88:522-6.
12. Nalini MS, Sinha M. Role of T-scan in digital occlusal analysis - a review. IJRRD 2018;1:1-7.
13. Kürklüarpacay D, Bayindir F, Dinçkalyanikoğlu N. Evaluation of premature contacts using the T-Scan III. Open J Stomatol 2019;9:136-45.
14. Niwatcharoenchaikul W, Tumrasvin W, Arksornnukit M. Effect of complete denture occlusal schemes on masticatory performance and maximum occlusal force. J Prosthet Dent 2014;112: 1337-42.
15. Jauregi M, Amezua X, Iturrate M, Solaberrieta E. Repeatability and reproducibility of 2 digital occlusal analyzers for measuring the right- and left-side balance of occlusal contact forces: An in vitro study. J Prosthet Dent 2024;132:179-87.
16. Lee W, Kwon HB, Kim MJ, Lim YJ. Determination of the reliability and repeatability of a quantitative occlusal analyzer by using a piezoelectric film sensor: An in vitro study. J Prosthet Dent 2022;127: 331-7.

디지털 교합 분석 장치를 이용한 교합 개선 중점의 총의치 및 임플란트 피개의치 수복 증례

이가현 전공의, **조영은** 조교수, **송영균*** 부교수
단국대학교 치과대학 치과보철학교실

총의치 환자들은 오랜 의치의 사용으로 의치 마모에 따른 저작력 감소를 경험한다. 조기 접촉점의 유무나 부적절한 양측성 균형교합의 형성은 의치의 안정을 방해하며 환자의 의치사용을 어렵게 한다. 기존의 정성적인 교합 기록은 환자 구내 교합관계를 평가하기에 한계점이 있었다. 이를 보완하고자 디지털 교합분석기를 활용한 정량적 교합분석을 통해 총의치 수복 시 구내에서의 보철물 교합력 확인, 교합점의 접촉 순서 및 강도, 밀도를 중심교합 및 편심교합에서 분석하였다. 해당 증례에서는 저작효율 감소를 호소한 총의치 환자에게 디지털 교합 분석 장치를 이용한 정량적 교합분석을 활용하여 총의치 및 하악 임플란트 피개의치 수복을 통해 교합 재건을 도모하였다. 위와 같은 분석이 기존 의치의 교합 문제점 파악, 치료 과정의 점검, 최종 의치의 양측성 균형교합의 설정에 실용적이었고 유용하게 활용될 수 있음을 확인하였다. 단, 디지털 교합 분석기의 필름의 손상 가능성, 다 회 사용시 감소하는 정확성 등의 기술적 한계점을 고려할 필요가 있다.

(구강회복응용과학지 2025;41(1):46-58)

주요어: 균형 교합; 임플란트 피개의치; 총의치

*교신저자: 송영균
(31116)충청남도 천안시 동남구 단대로 119 단국대학교 치과대학 치과보철학교실
Tel: 041-550-1932 | Fax: 041-550-0256 | E-mail: ygsong@dankook.ac.kr
접수일: 2024년 10월 10일 | 수정일: 2024년 10월 29일 | 채택일: 2024년 11월 13일