https://doi.org/10.14368/jdras.2025.41.4.323
ISSN 2384-4353 eISSN 2384-4272

Case Report

Minimally invasive sinus irrigation (MISI) via extraction site for odontogenic maxillary sinusitis: a case report

Yeon-Ju Jung[1†], Yerim Oh[2†], In-Kyung Hwang[1], Heung-Sik Um[1], Jae-Kwan Lee[1*]

[1]*Department of Periodontology and Research Institute for Oral Sciences, Gangneung-Wonju National University College of Dentistry, Gangneung, Republic of Korea*

[2]*Department of Periodontics, Dankook University Jukjeon Dental Hospital, Yongin, Republic of Korea*

Odontogenic maxillary sinusitis (OMS) can compromise implant osseointegration and increase the risk of postoperative complications. Although antibiotic therapy is generally the first-line treatment, refractory cases often require surgical intervention. This case report describes a minimally invasive sinus irrigation (MISI) technique as an alternative approach to conventional sinus surgery. In Case 1, a 73-year-old female with persistent OMS after implant failure underwent MISI via the explantation site at #15. In Case 2, a 56-year-old male with right-sided OMS unresponsive to antibiotics was treated with MISI through the extraction socket at #16. Both procedures were performed under local anesthesia using dual-needle irrigation with saline and chlorhexidine. Radiographic evidence confirmed resolution of sinusitis within 8 to 10 days, and subsequent implant placement was successfully completed without complications. MISI demonstrated clinical efficacy in resolving OMS and may offer a less invasive option compared to traditional lateral wall approaches. Further studies are needed to validate long-term outcomes. **(J Dent Rehabil Appl Sci 2025;41(4):323-33)**

Key words: dental implants; maxillary sinus; osseointegration; sinusitis; therapeutic Irrigation

Introduction

Odontogenic maxillary sinusitis (OMS) accounts for 10 - 12% of maxillary sinusitis cases, and its iatrogenic incidence is increasing, often due to minor dental procedures.[1] The presence of OMS prior to implant surgery has been shown to elevate the risk of postoperative sinusitis.[2] Moreover, OMS can impair implant osseointegration, leading to implant failure,[2] and may delay extraction socket healing, potentially resulting in an oroantral fistula. Therefore, thorough evaluation and appropriate management of OMS are essential prior to any dental treatment to prevent complications and ensure optimal surgical outcomes.

Antibiotic therapy is typically the first-line treatment for managing OMS, as pharmacologic intervention is initially preferred to control infection. In selecting an antibiotic regimen, amoxicillin combined with clavulanate is generally recommended due to its broad-spectrum activity against both aerobic and anaerobic bacteria.[3] For patients with confirmed penicillin allergies, alternative agents such as fluoroquinolones or tetracyclines may be considered.[4] Ideally, antibiotic selection should be guided by local bacte-

*Correspondence to: Jae-Kwan Lee
Professor, Department of Periodontology and Research Institute for Oral Sciences, Gangneung-Wonju National University College of Dentistry, 7, jukheon-gil, Gangneung, 25457, Republic of Korea
Tel: +82-33-640-3199, Fax: +82-33-640-3103, E-mail: periojk@gwnu.ac.kr
†Contributed equally to this work as first authors.
Received: August 5, 2025/Last Revision: September 12, 2025/Accepted: September 27, 2025

Copyright© 2025 The Korean Academy of Stomatognathic Function and Occlusion.
It is identical to Creative Commons Non-Commercial License.

rial resistance patterns to ensure optimal outcomes.[3-6]

When antibiotic therapy fails to resolve the infection, surgical intervention becomes necessary. The classical Caldwell-Luc procedure involves creating an opening in the anterior maxillary wall under general anesthesia; however, it is associated with significant morbidity.[6] Maxillary sinus irrigation, an alternative surgical approach, entails opening the lateral wall of the maxillary sinus and irrigating it with normal saline. Compared with the Caldwell-Luc procedure, sinus irrigation is associated with fewer complications, faster mucosal recovery, and can be performed under local anesthesia. Several studies have reported that sinus irrigation improves maxillary sinusitis by reducing mucosal permeability and alleviating associated clinical symptoms.[5-7]

Despite these advantages, clinical reports evaluating the effectiveness of sinus irrigation specifically for OMS remain limited. Traditionally, sinus irrigation requires creating an access window in the lateral wall, which, while effective, still necessitates surgical osteotomy and flap elevation. In contrast, this case report introduces minimally invasive sinus irrigation (MISI) – a simplified technique that utilizes the existing extraction socket or implant removal site as the access point for irrigation, eliminating the need for separate lateral wall opening. This approach reduces surgical invasiveness and may shorten healing time. Therefore, we report two cases of antibiotic-refractory OMS successfully managed with MISI technique.

Case Reports

Case 1

A 73-year-old female with well-controlled hypertension presented for implant placement in multiple edentulous sites (#13, #15, #34, #36, #44, and #46) (Fig. 1). Nonsurgical periodontal therapy, including scaling and root planing, was completed before implant placement. For the maxillary right canine and second molar sites (#13 and #15), transcrestal sinus floor elevation (TSFE) with simultaneous implant placement (Sola Φ4.5 × 10 mm, Shinhung, Seoul, Korea) was performed (Fig. 2A-E).

Until after 1 month postoperatively, there were no symptoms or clinical signs of complications. Soft tissue healing was interpreted as consistent with secondary intention, based on the patient's history of delayed healing.

At 2.5 months, during second-stage surgery, the pre-elevation clinical view showed no clinical signs of infection (Fig. 3A). After flap reflection, slight bluish mucosal discoloration with purulent exudate was observed (Fig. 3B). The implant was removed (Fig. 3D). Despite saline irrigation, purulent discharge persisted; the site was closed with sutures (Fig. 3C).

Waters' view radiography revealed right maxillary sinus opacification with radiopaque material (Fig. 4A). A 7-day course of amoxicillin-clavulanate was prescribed, resulting in partial radiographic improvement (Fig. 4B). However, despite referral to an

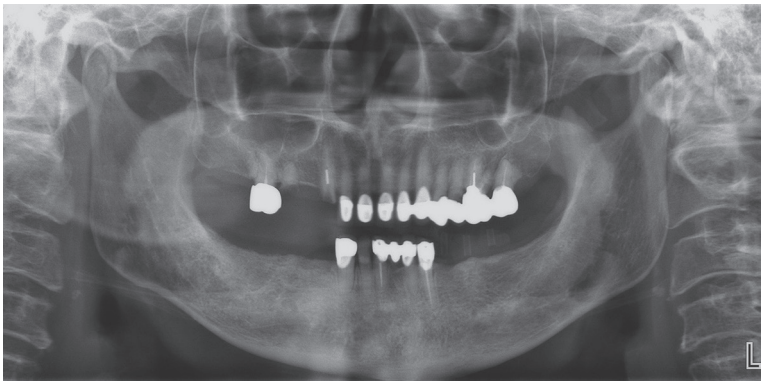

Fig. 1. Preoperative panoramic radiograph.

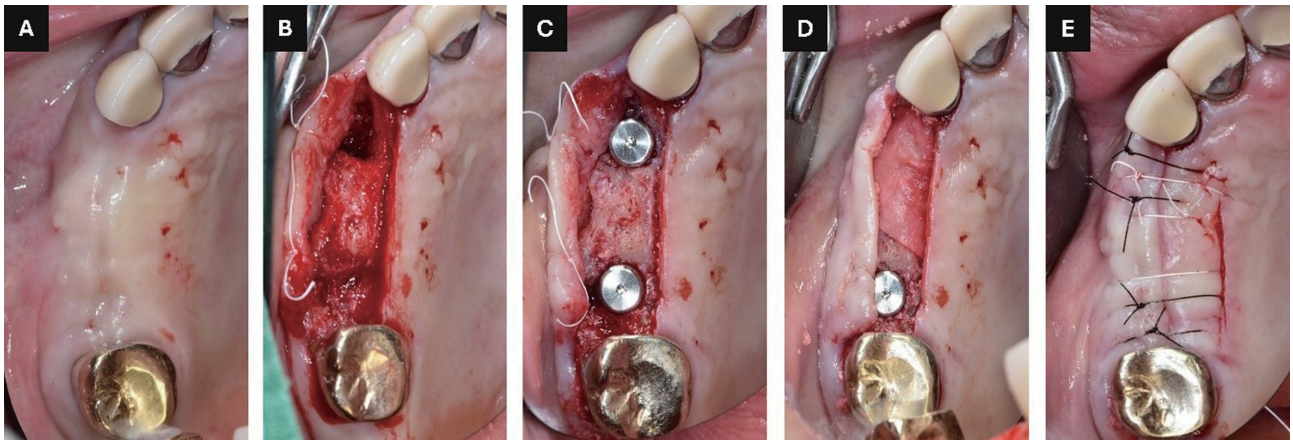

Fig. 2. Clinical photographs illustrate transcrestal sinus floor elevation and implant placement at sites #13 and #15. (A) preoperative intraoral view, (B) flap elevation, (C) implant fixture placement, (D) GBR at site #13 using DBBM and collagen membrane, and bone grafting with DBBM at site #15, and (E) primary wound closure with sutures.
GBR: guided bone regeneration; DBBM: deproteinized bovine bone mineral.

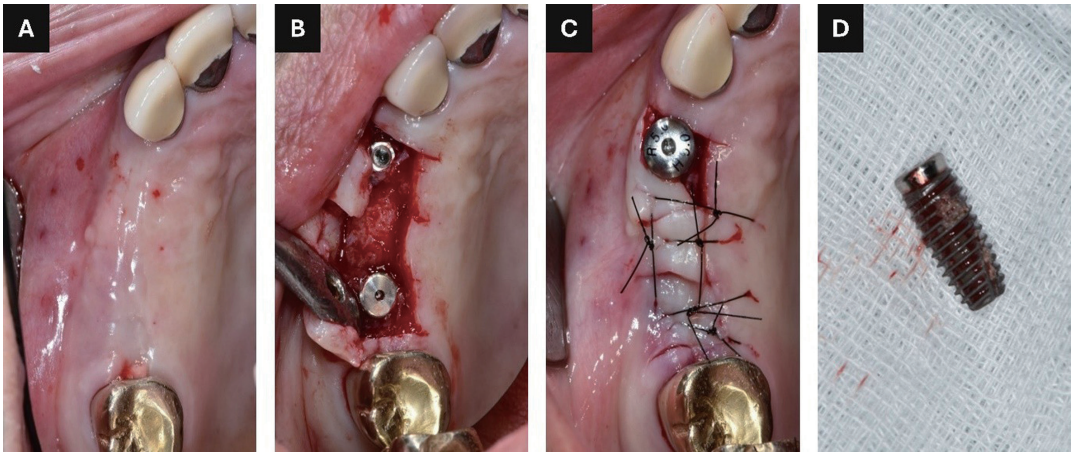

Fig. 3. Intraoperative findings and implant removal. (A) Pre-elevation view of the implant site showing no clinical signs of infection, (B) Flap reflection revealing slight bluish mucosal discoloration with purulent exudate, (C) Saline irrigation through the explantation site, followed by primary closure with sutures, (D) Removed implant fixture.

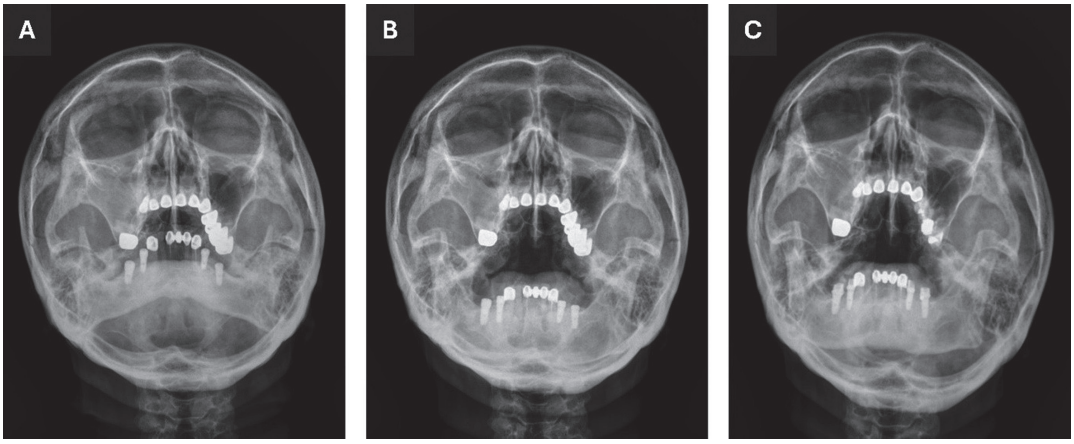

Fig. 4. Waters' view radiographs. (A) Maxillary sinus opacification observed prior to treatment, (B) Partial radiographic improvement following antibiotic therapy, (C) Persistent sinusitis despite extended medical management.

otolaryngologist and an additional 1-month medical regimen, sinus opacification persisted (Fig. 4C).

MISI was performed through the implant removal site at the maxillary right first premolar (#15). A crestal incision was made, and aspiration confirmed purulent exudate (Fig. 5A, 5B). Dual-needle irrigation was performed: one 21-gauge needle connected to suction penetrated the sinus floor for continuous aspiration, while a second 21-gauge needle attached to a 20-cc syringe was used to irrigate the area ten times with saline and five times with chlorhexidine gluconate solution 0.12% (Hexamedine®; Bukwang Pharm. Co., Ltd., Seoul, Korea). over 10 minutes until the discharge is resolved (Fig. 5C). The site was covered with absorbable collagen wound dressing (CollaTape®; Zimmer Biomet, Warsaw, USA) and absorbable atelocollagen sponge plug (Ateloplug®; Hyundai Bioland, Cheonan, Korea). Closure was achieved with simple interrupted sutures using 5-0 black nylon (Ailee Co., Busan, Korea) (Fig. 5D). Postoperative medications included amoxicillin-clavulanate (Augmentin®, 375 mg; Ilsung Pharmaceuticals, Seoul, Korea), administered p.o. t.i.d. for 7 days; metronidazole (Flasinyl®, 500 mg; HK inno.N, Seoul, Korea), administered p.o. t.i.d. for 7 days; and pseudoephedrine (Sudafed®, 60 mg; Samil Pharmaceuti-

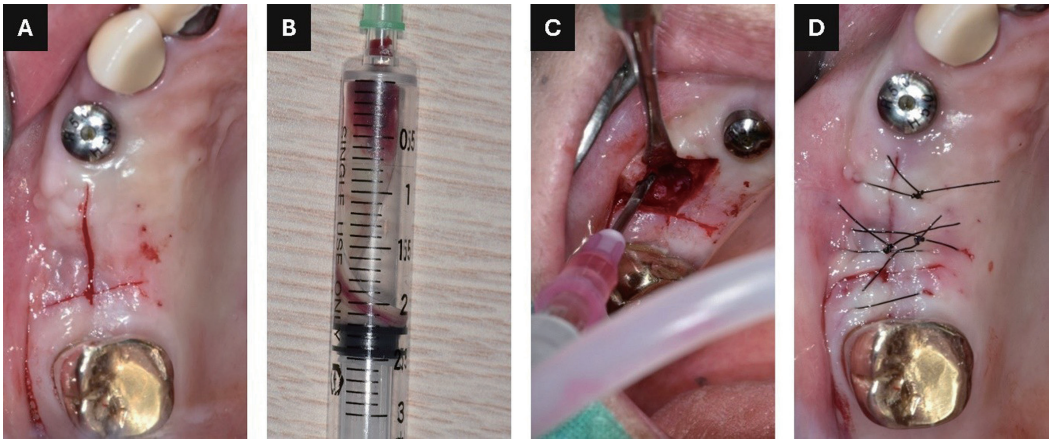

Fig. 5. MISI procedure performed the implant removal site at #15. (A) Crestal incision, (B) Aspiration confirming purulent exudate using a 3-cc syringe, (C) Dual-needle irrigation with saline and chlorhexidine solution, (D) Primary closure achieved with simple interrupted sutures.
MISI: minimally invasive sinus irrigation.

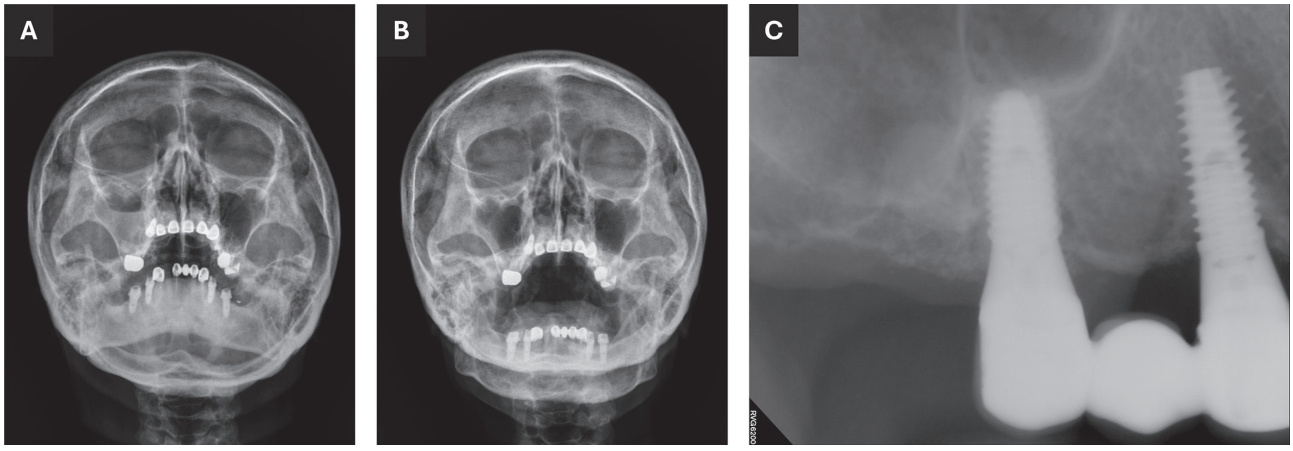

Fig. 6. Radiographic and clinical outcomes following MISI. (A) Waters' view radiograph obtained immediately after MISI, showing partial resolution of maxillary sinus opacification, (B) Waters' view radiograph 10 days postoperatively, demonstrating markedly improved sinus aeration, (C) Radiograph showing successful re-implantation at site #15.

cal, Seoul, Korea), administered p.o. t.i.d. for 3 days. Radiographs demonstrated improved sinus aeration within 10 days (Fig. 6A, 6B). Three months later, reimplantation at site #15 (Sola Φ4.5 × 10 mm) was successfully completed without complications. The definitive restorations were delivered 5 months after reimplantation, and the 1-year follow-up revealed stable peri-implant conditions without complications (Fig. 6C).

Case 2

A 56-year-old male with well-controlled hypertension, type 2 diabetes mellitus, hyperlipidemia, and a one-pack daily smoking history presented with pain in maxillary molars (#16, 27). Extractions and implant placements were planned at molar areas (#16, 17, 27, 37, and 47) (Fig. 7). Cone beam computed tomography (CBCT) revealed insufficient alveolar bone height at maxillary right molar (#16 and #17), and right maxillary sinusitis with suspected oroantral fistula (Fig. 8A).

Amoxicillin-clavulanate was prescribed for 14 days without improvement (Fig. 8B); therefore, MISI was performed. A crestal incision at maxillary right first molar and vertical release at maxillary right first premolar (#14) were made to elevate the flap (Fig. 9A). Incomplete healing and purulent discharge were observed during curettage (Fig. 9B). Dual-needle irrigation with saline and chlorhexidine was performed as in Case 1 (Fig. 9C).

The site exhibited the perforation of a Schneide-

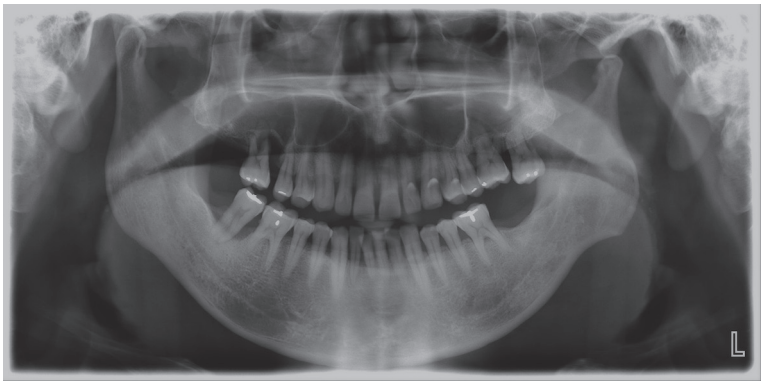

Fig. 7. Initial panoramic radiograph showing the molar areas (#16, 17, 27, 37, and 47) planned for extractions and implant placements.

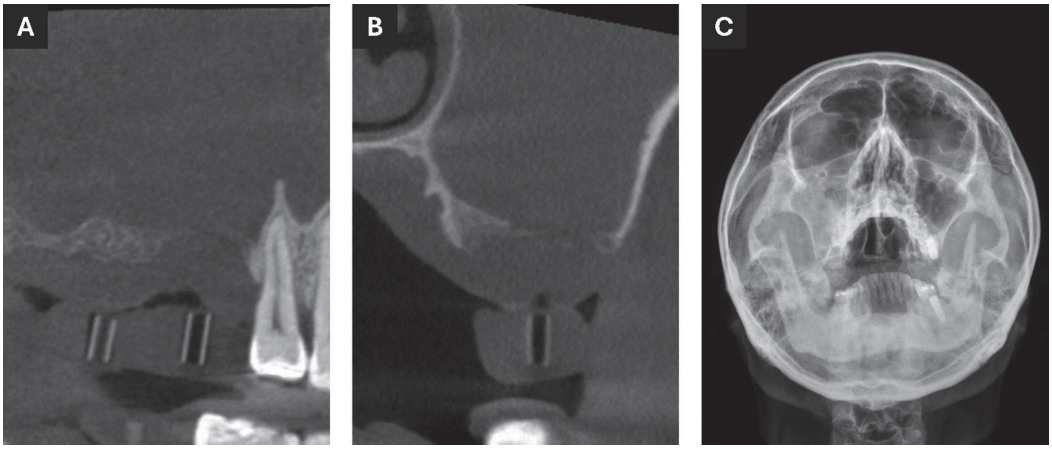

Fig. 8. Preoperative radiographic findings. (A, B) CBCT images showing insufficient alveolar bone height at sites #16 and #17, along with right maxillary sinus opacification suggestive of sinusitis, (C) Waters' view radiograph obtained after 14 days of antibiotic therapy, demonstrating persistent right maxillary sinusitis.

rian membrane; therefore, a collagen wound dressing (CollaTape®; Zimmer Biomet) was applied, followed by extra-antral, crestal guided bone regeneration (GBR) of the alveolar defect using particulate deproteinized bovine bone mineral deproteinized bovine bone mineral (Bio-Oss®; Geistlich Pharma, Wolhusen, Switzerland) beneath a resorbable collagen membrane (Bio-Gide®; Geistlich Pharma), without deliberate placement of graft material into the sinus cavity at this stage (Fig. 9D).[6] Postoperative antibiotics included amoxicillin/clavulanate and metronidazole for 7 days. The flap was closed with simple interrupted sutures (Fig. 9E). Waters' view radiographs demonstrated resolution of sinusitis within 8 days (Fig. 10A). Healing was uneventful, and five months later, implants were placed at maxillary right 1st, and 2nd molar with TSFE (Sola Φ4.5 × 10 mm) without complications (Fig. 10B). The definitive restorations were completed approximately 6 months postoperatively, and no complications were observed at the 4-month follow-up.

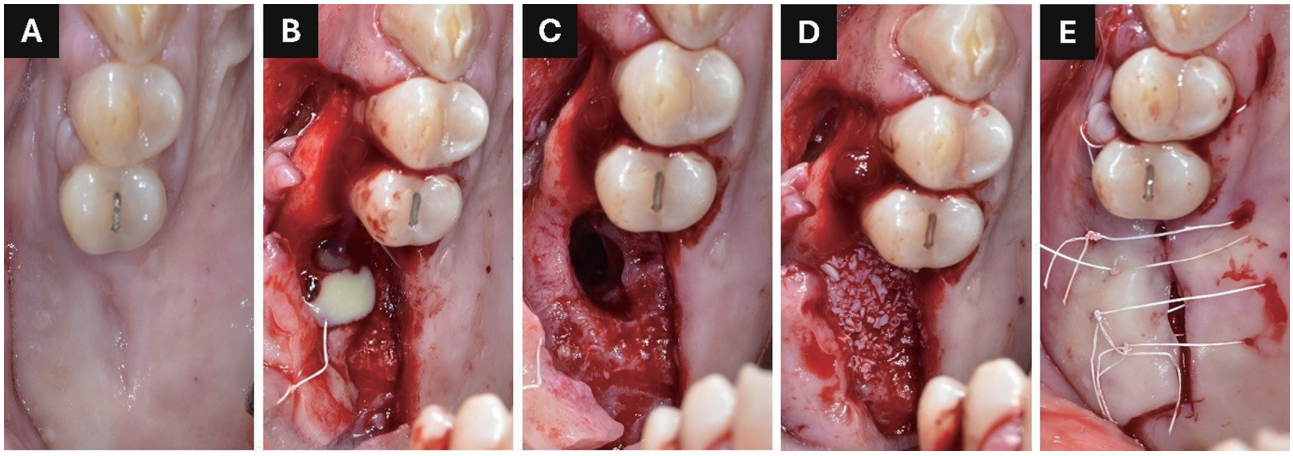

Fig. 9. MISI and guided bone regeneration procedure. (A) Preoperative occlusal view of site #16, (B) Purulent discharge observed during curettage of the sinus floor, (C) Dual-needle irrigation is performed with saline and chlorhexidine, (D) GBR using DBBM and resorbable collagen membrane (Bio-Gide®), (E) Flap closure was achieved with simple interrupted sutures.

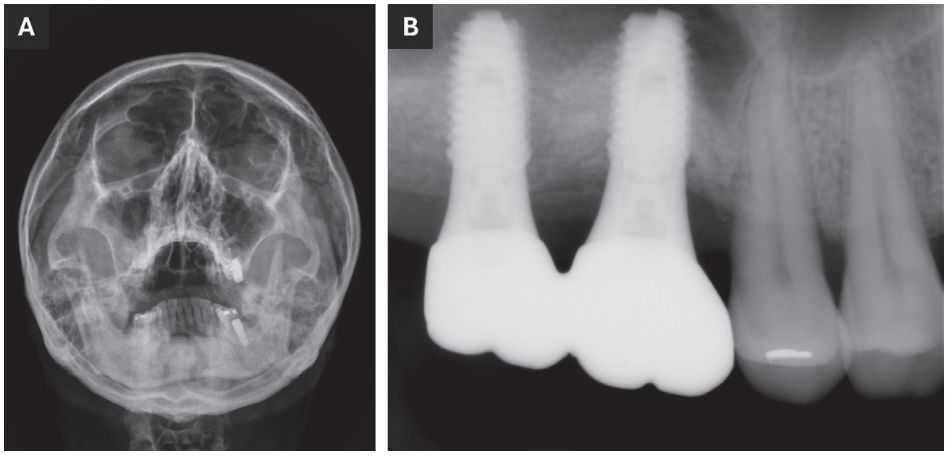

Fig. 10. Postoperative follow-up and implant placement. (A) Waters' view radiograph was obtained 8 days after MISI, showing improved sinus aeration, (B) Postoperative photograph following successful implant placement at sites #16 and #17.

Discussion

Most unilateral maxillary sinusitis cases are either acute or chronic bacterial sinusitis or fungal ball. The causes include infections of the maxillary posterior teeth, pathologic lesions, trauma, and iatrogenic injury from dental implant procedures such as sinus floor elevation.[8] The precise pathophysiology of fungal ball is not fully understood, however it has been associated with dental procedures involving endodontic treatment and obturation materials.[9]

OMS is characterized by halitosis and purulent discharge from the middle meatus, with α-hemolytic streptococci and anaerobic bacteria being common pathogens.[10,11] Accurate diagnosis is critical, as Longhini & Ferguson[12] reported that dental lesions were not detected clinically in 86% of OMS cases, underscoring the need for careful radiographic evaluation. Therefore, when OMS is suspected, careful review of imaging studies is essential. Without addressing the dental origin, medical or surgical treatment often fails and symptoms persist.

In Case 1, retrospective review revealed a missed fistulous tract at site #15, highlighting the diagnostic challenges in OMS. Furthermore, persistent purulent discharge was noted, and initial irrigation was inadequate due to inexperience managing such sinus complications. During the irrigation of the explantation site, there was a concern of an oroantral communication due to nasal egress of irrigant. To avoid exacerbating infection or aspiration, MISI was deferred and otolaryngology evaluation was prioritized to assess the need for drainage and to confirm ostiomeatal complex patency. These findings emphasize the importance of thorough clinical examination and readiness to manage postoperative infections to prevent delays and morbidity.

Panoramic radiography is helpful for evaluating tooth-sinus relationship and detecting foreign bodies. However, it has limitations in assessing the entire maxillary sinus.[13] CT is considered the gold standard for diagnosing maxillary sinus diseases due to high-resolution imaging of bone and soft tissue. CBCT widely used in dentistry, provides detailed bony images at a fraction of the radiation dose of conventional CT, though soft tissue resolution is limited.[4]

Complete resolution of infection and prevention of recurrence or complications require simultaneous treatment of maxillary sinusitis and its dental source. Removal of root fragments, extraction of the infected tooth, or endodontic treatment is essential to prevent recurrence.[1,13-15]

OMS can compromise implant osseointegration and delay postoperative healing. Active sinus infection increases the risk of implant failure, necessitating appropriate medical or surgical management to establish a healthy sinus before implant placement. Although sinus lift procedures are often necessary to increase alveolar bone height, they can precipitate OMS, leading to severe complications such as orbital cellulitis or intracranial infections. Therefore, thorough preoperative assessment and management of OMS are critical to minimizing these risks.[4]

Nonsurgical treatment is the first and most important step in managing OMS. This includes antibiotic therapy, intranasal corticosteroids, and irrigation. Because bacterial infection plays a major role in OMS, antibiotic therapy is particularly important. In these cases, a combination of amoxicillin/clavulanate and metronidazole was used to cover aerobic and anaerobic bacteria. Amoxicillin/clavulanate was administered for 5 to 10 days, in accordance with the 2015 AAO-HNSF guideline for acute bacterial rhinosinusitis, and metronidazole was added to enhance anaerobic coverage commonly implicated in odontogenic maxillary sinusitis.[16,17] While amoxicillin/clavulanate is effective against aerobic and β-lactamase-producing organisms, metronidazole enhances coverage against obligate anaerobes. Therefore, combination therapy was employed to ensure comprehensive antimicrobial coverage and optimize infection control prior to surgical intervention.[14]

When conservative measures fail, surgical treatment is indicated. The Caldwell-Luc procedure, though historically common, can cause sinus wall sclerosis, osteomyelitis, and impaired mucociliary function. It is also associated with intraoperative bleeding, infraorbital nerve injury, and various postoperative complications such as facial swelling, buccal discomfort, pain, hemorrhage, and fever.[18] Long-term complica-

tions may include facial asymmetry, hypoesthesia or paresthesia of the face and teeth, oroantral fistula, gingivolabial wound dehiscence, dacryocystitis, facial pain, pulp necrosis, recurrence of sinusitis, recurrent polyps, and sinus wall sclerosis.[18]

Currently, functional endoscopic sinus surgery (FESS) and maxillary sinus irrigation[7] have become established alternative treatments for sinusitis. Recently, in addition to conventional FESS, minimally invasive sinus techniques (MIST)–including balloon sinus ostial dilation–have also been selectively utilized in the management of various sinonasal diseases.[19] However, because of the heterogeneity of the current evidence, such approaches should be reserved for carefully selected patients who meet radiologic and symptomatic criteria and, particularly in odontogenic maxillary sinusitis, applied in a stepwise manner in conjunction with causal dental treatment.[15] These less invasive procedures allow treatment of hypertrophic and infected mucosa and are associated with lower morbidity.[7] In particular, MISI performed through the extraction socket further reduces surgical invasiveness, decreases operative time, and promotes faster recovery. These cases demonstrate that MISI effectively resolved OMS even when antibiotic treatment fails, allowing subsequent implant placement and uncomplicated healing. Additionally, in both cases, Waters' view radiographs showed increased aeration within the maxillary sinus approximately 10 days after MISI, indicating rapid improvement in sinus ventilation. MISI not only avoids the morbidity associated with traditional Caldwell-Luc surgery but also facilitates rapid recovery and re-implantation.

The success rate of conservative treatment has been reported to vary widely, ranging from 36% to 95% across studies. This variation also indicates that the failure or recurrence rate can reach up to 64% in certain cases when conservative therapy is attempted. In contrast, surgical treatment in Rangics et al. (2023) demonstrated a 96.4% success rate (3.6% recurrence), and large-scale studies have also reported consistently high success rates of 90 - 99% or higher.[20] Therefore, when conservative treatment fails, surgical management provides clearly superior outcomes in terms of prognosis and recurrence.

From a practical standpoint, MISI is particularly advantageous in the management of OMS. It is most beneficial when symptoms persist despite appropriate nonsurgical therapy, and when the disease is localized to the maxillary sinus adjacent to the dental source. MISI is especially suited for situations where access via an extraction socket or explantation site allows effective lavage and debridement under local anesthesia. In such cases, rapid infection control can be achieved, enabling timely implant placement with sinus bone augmentation and prosthetic rehabilitation. Conversely, MISI should not be applied in cases complicated by conditions such as cysts, polyps, tumors, or medication-related osteonecrosis of the jaw (MRONJ).[5] These considerations help define the appropriate clinical indications for MISI in OMS management, ensuring its safe and effective application.

In cases of OMS, once sinusitis is resolved through MISI, subsequent implant placement can generally proceed according to standard protocols, provided that stable ridge conditions are achieved. As highlighted in the recent expert consensus, when the sinus floor bone remains continuous or the sinus membrane is intact after tooth extraction or explantation, alveolar ridge preservation is advocated to preserve adequate bone volume. In situations where membrane perforation occurs, sinus membrane repair should be performed to re-establish an intact barrier. With these adjunctive procedures, thereby providing a favorable foundation for implant placement with minimal risk.[6]

The limitations of this report include the small sample size, lack of control group, and absence of objective outcome measures such as operation time, postoperative pain, and healing period. Future prospective studies are needed to validate these findings.

Accurate diagnosis and appropriate management of OMS are essential to improving implant success rates and reducing postoperative complications.

Conclusion

MISI effectively resolved odontogenic maxillary sinusitis in patients unresponsive to conservative therapy, enabling successful implant placement with-

out complications. This technique provides a less invasive alternative to traditional surgical procedures, reducing morbidity and facilitating faster recovery. Although these initial results are promising, larger prospective studies are needed to compare MISI with established surgical interventions and assess its long-term impact on implant success. Careful preoperative diagnosis and management of OMS remain essential for optimizing outcomes in implant dentistry.

ORCID

Yeon-Ju Jung https://orcid.org/0009-0002-3172-2498
Yerim Oh https://orcid.org/0009-0004-4014-1075
In-Kyung Hwang https://orcid.org/0000-0002-3238-9466
Heung-Sik Um https://orcid.org/0000-0002-7986-1019
Jae-Kwan Lee https://orcid.org/0000-0003-1710-1580

References

1. Mehra P, Jeong D. Maxillary sinusitis of odontogenic origin. Curr Allergy Asthma Rep 2009;9:238-43.
2. Kim JS, Choi SM, Yoon JH, Lee EJ, Yoon J, Kwon SH, Yeo CD, Ryu JS, Lee JH, You YS, Kim SG, Lee MH, Han BH. What affects postoperative sinusitis and implant failure after dental implant: a meta-analysis. Otolaryngol Head Neck Surg 2019;160:974-84.
3. Vidal F, Coutinho TM, Carvalho Ferreira D, Souza RC, Gonçalves LS. Odontogenic sinusitis: a comprehensive review. Acta Odontol Scand 2017;75:623-33.
4. Psillas G, Papaioannou D, Petsali S, Dimas GG, Constantinidis J. Odontogenic maxillary sinusitis: A comprehensive review. J Dent Sci 2021;16:474-81.
5. Jaiswal MS, Ha GB, Hwang JY, Lee JY, Hwang DS. Sinus irrigation as an adjunctive therapy for odontogenic maxillary sinusitis - an in-depth analysis. Maxillofac Plast Reconstr Surg 2024;46:20.
6. Lin J, Wang C, Wang X, Chen F, Zhang W, Sun H, Yan F, Pan Y, Zhu D, Yang Q, Ge S, Sun Y, Wang K, Zhang Y, Xian M, Zheng M, Mo A, Xu X, Wang H, Zhou X, Zhang L. Expert consensus on odontogenic maxillary sinusitis multi-disciplinary treatment. Int J Oral Sci 2024;16:11.
7. Gang N, JiaMin C, Ye W, FuPing X, HuanHuan L, LiSong L. Comparing the efficacy of sinus irrigation with traditional Caldwell-Luc procedure following odontogenic cyst surgery involving the maxillary sinus. Sci Rep 2021;11:18136.
8. Simuntis R, Kubilius R, Vaitkus S. Odontogenic maxillary sinusitis: a review. Stomatologija 2014;16:39-43.
9. Mensi M, Piccioni M, Marsili F, Nicolai P, Sapelli PL, Latronico N. Risk of maxillary fungus ball in patients with endodontic treatment on maxillary teeth: a case-control study. Oral Surg Oral Med Oral Pathol Oral Radiol Endod 2007;103:433-6.
10. Yassin-Kassab A, Bhargava P, Tibbetts RJ, Griggs ZH, Peterson EI, Craig JR. Comparison of bacterial maxillary sinus cultures between odontogenic sinusitis and chronic rhinosinusitis. Int Forum Allergy Rhinol 2021;11:40-7.
11. Kim TG, WhangBo CH, Lee SH, Ye MK, Shin SH. Clinical characteristics of odontogenic and non-odontogenic unilateral chronic maxillary sinusitis. Korean J Otorhinolaryngol-Head Neck Surg 2025;68:195-200.
12. Longhini AB, Ferguson BJ. Clinical aspects of odontogenic maxillary sinusitis: a case series. Int Forum Allergy Rhinol 2011;1:409-15.
13. Patel NA, Ferguson BJ. Odontogenic sinusitis: an ancient but under-appreciated cause of maxillary sinusitis. Curr Opin Otolaryngol Head Neck Surg 2012;20:24-8.
14. Brook I. Sinusitis of odontogenic origin. Otolaryngol Head Neck Surg 2006;135:349-55.
15. Lee KC, Lee SJ. Clinical features and treatments of odontogenic sinusitis. Yonsei Med J 2010;51:932-7.
16. Rosenfeld RM, Piccirillo JF, Chandrasekhar SS, et al. Clinical practice guideline (update): adult sinusitis. Otolaryngol Head Neck Surg 2015;152(2 Suppl):S1-S39.
17. Bali R, Sharma P, Gaba S. Use of metronidazole as part of an empirical antibiotic regimen after incision and drainage of infections of the odontogenic spaces. Br J Oral Maxillofac Surg 2015;53:18-22.
18. Defreitas J, Lucente FE. The Caldwell-Luc procedure: institutional review of 670 cases: 1975-1985. Laryngoscope 1988;98:1297-300.

19. Fokkens WJ, Lund VJ, Hopkins C, Hellings PW, Kern R, Reitsma S, Toppila-Salmi S, Bernal-Sprekelsen M, Mullol J, Alobid I, Anselmo-Lima WT, Bachert C, Baroody F, von Buchwald C, Cervin A, Cohen N, Constantinidis J, De Gabory L, Desrosiers M, Diamant Z, Douglas RG, Gevaert PH, Hafner A, Harvey RJ, Joos GF, Kalogjera L, Knill A, Kocks JH, Landis BN, Limpens J, Lebeer S, Lourenco O, Meco C, Matricardi PM, O'Mahony L, Philpott CM, Ryan D, Schlosser R, Senior B, Smith TL, Teeling T, Tomazic PV, Wang DY, Wang D, Zhang L, Agius AM, Ahlstrom-Emanuelsson C, Alabri R, Albu S, Alhabash S, Aleksic A, Aloulah M, Al-Qudah M, Alsaleh S, Baban MA, Baudoin T, Balvers T, Battaglia P, Bedoya JD, Beule A, Bofares KM, Braverman I, Brozek-Madry E, Richard B, Callejas C, Carrie S, Caulley L, Chussi D, de Corso E, Coste A, El Hadi U, Elfarouk A, Eloy PH, Farrokhi S, Felisati G, Ferrari MD, Fishchuk R, Grayson W, Goncalves PM, Grdinic B, Grgic V, Hamizan AW, Heinichen JV, Husain S, Ping TI, Ivaska J, Jakimovska F, Jovancevic L, Kakande E, Kamel R, Karpischenko S, Kariyawasam HH, Kawauchi H, Kjeldsen A, Klimek L, Krzeski A, Kopacheva Barsova G, Kim SW, Lal D, Letort JJ, Lopatin A, Mahdjoubi A, Mesbahi A, Netkovski J, Nyenbue Tshipukane D, Obando-Valverde A, Okano M, Onerci M, Ong YK, Orlandi R, Otori N, Ouennoughy K, Ozkan M, Peric A, Plzak J, Prokopakis E, Prepageran N, Psaltis A, Pugin B, Raftopulos M, Rombaux P, Riechelmann H, Sahtout S, Sarafoleanu CC, Searyoh K, Rhee CS, Shi J, Shkoukani M, Shukuryan AK, Sicak M, Smyth D, Sindvongs K, Kosak TS, Stjarne P, Sutikno B, Steinsvag S, Tantilipikorn P, Thanaviratananich S, Tran T, Urbancic J, Valiulius A, de Aparicio CV, Vicheva D, Virkkula PM, Vicente G, Voegels R, Wagenmann MM, Wardani RS, Welge-Lussen A, Witterick I, Wright E, Zabolotniy D, Zsolt B, Zwetsloot CP. European position paper on rhinosinusitis and nasal polyps 2020. Rhinology 2020;58 Suppl 29:1-464.
20. Rangics A, Répássy GD, Gyulai-Gaál S, Dobó-Nagy C, Tamás L, Simonffy L. Management of odontogenic sinusitis: Results with single-step FESS and dentoalveolar surgery. J Pers Med 2023;13:1291.

발치 부위를 통한 최소 침습 상악동 세정을 이용한 치성 상악동염의 치료 효과: 증례 보고

정연주[1†] 대학원생, **오예림**[2†] 조교수, **황인경**[1] 조교수, **엄흥식**[1] 교수, **이재관**[1*] 교수

[1]강릉원주대학교 치과대학 치주과학교실 및 구강과학연구소

[2]단국대학교죽전치과병원 치주과

치성 상악동염(Odontogenic maxillary sinusitis, OMS)은 치과 임플란트의 골유착을 저해하고 수술 후 합병증의 위험을 증가시킬 수 있다. 일반적으로 항생제 치료가 1차 치료로 사용되지만, 초기 치료에 반응하지 않는 경우에는 외과적 처치가 필요하다. 이번 증례보고에서는 기존의 외과적 술식에 대한 대안으로 최소 침습적 상악동 세척(minimally invasive sinus irrigation, MISI)의 효과를 기술하고자 한다. 증례 1에서는 임플란트 실패 후 지속적인 OMS을 보인 73세 여성 환자에게 #15 부위 제거 부위를 통한 MISI를 시행하였고, 증례 2에서는 항생제 치료에 반응하지 않은 상악 우측 OMS를 가진 56세 남성 환자에게 #16 발치와를 통한 MISI를 적용하였다. 두 증례 모두 국소마취 하에 생리식염수 및 클로르헥시딘을 이용한 이중 주사침 세척을 시행하였으며, 8 - 10일 이내 영상학적으로 상악동염의 호전을 확인하였다. 이후 임플란트 재식립이 합병증 없이 성공적으로 완료되었다. MISI는 OMS에 효과적인 치료법으로, 기존의 외과적 개창술에 비해 침습성이 낮은 유용한 대안이 될 수 있다. 특히 초기 항생제 치료와 치과적 처치에 반응하지 않는 환자에서 시행될 수 있는 적절한 치료 옵션이다. 장기적인 예후에 대한 추가 연구가 필요하다. (구강회복응용과학지 2025;41(4):323-33)

주요어: 치과용 임플란트; 상악동; 상악동염; 골유착; 치료적 세정

*교신저자: 이재관

(25457)강원특별자치도 강릉시 죽헌길 7 강릉원주대학교 치과대학 치주과학교실 및 구강과학연구소

Tel: 033-640-3199 | Fax: 033-640-3103 | E-mail: periojk@gwnu.ac.kr

접수일: 2025년 8월 5일 | 수정일: 2025년 9월 12일 | 채택일: 2025년 9월 27일

†이 연구에 제1저자로 동일한 기여를 하였음.