https://doi.org/10.14368/jdras.2025.41.4.344
ISSN 2384-4353 eISSN 2384-4272

Case Report

Anterior implant-supported fixed prosthetic rehabilitation with occlusal splint therapy for panfacial trauma: a case report and clinical insights

Jeong-in Shin[1], Jong-jin Kim[1], Joohee Lee[1,2], Jin Baik[1], Hyunsuk Cha[1,2]*
[1]*Department of Prosthodontics, Asan Medical Center, Seoul, Republic of Korea*
[2]*College of Medicine, University of Ulsan, Ulsan, Republic of Korea*

This report presents the prosthetic rehabilitation of a 32-year-old male who sustained panfacial fractures and anterior tooth loss after a traffic accident. Despite reoperation following initial fixation, malocclusion and temporomandibular joint displacement persisted due to fibrous adhesions, limiting functional recovery. A one-year course of occlusal splint therapy stabilized the joint and improved occlusion, after which anterior implants were placed using digital planning. A key feature of this case was the application of screw- and cement-retained prostheses that maintained fixation while allowing retrievability, chosen in consideration of the patient's age and preference despite severe bone loss where removable prostheses are typically indicated. Long-term splint therapy contributed to functional stabilization and supported favorable outcomes of the prosthetic treatment. This case highlights how combining digital implant planning with conservative occlusal therapy can provide predictable functional and esthetic rehabilitation in patients with complex post-traumatic deformities. **(J Dent Rehabil Appl Sci 2025;41(4):344-53)**

Key words: panfacial fractures; temporomandibular joint displacement; occlusal splints; removable implant; screw- and cement-retained prostheses; digital implant planning

Introduction

Severe maxillofacial trauma involving extensive bone defects poses significant challenges in restoring both function and esthetics. Prosthetic rehabilitation is essential not only for recovering mastication and speech but also for restoring facial contour and psychological well-being.[1] However, these cases are complicated by loss of anatomical landmarks, compromised bone quality and volume, and altered occlusal relationships caused by trauma and initial surgical interventions.[2,3]

Patients with panfacial fractures often present with unstable occlusion, limited mandibular mobility, and temporomandibular joint (TMJ) dysfunction, which complicate treatment planning.[1] The choice between fixed and removable prostheses must be guided by the degree of bone and soft tissue loss, as fixed options are frequently limited by hypercontoured restorations and hygiene challenges.[2] Moreover, surgical reconstruction alone may not fully restore occlusal harmony or TMJ function, underscoring the need for adjunctive therapies to optimize functional rehabilitation.[4,5]

Occlusal splints, in particular, can stabilize the TMJ, reduce muscular tension, and gradually im-

*Correspondence to: Hyunsuk Cha
Professor, Department of Prosthodontics, Asan Medical Center, 88, Olympic-ro 43-gil, Songpa-gu, Seoul, 05505, Republic of Korea
Tel: +82-2-3010-3847, Fax: +82-2-3010-6967, E-mail: chahyunsuk@hanmail.net
Received: October 1, 2025/Last Revision: October 15, 2025/Accepted: October 17, 2025

Copyright© 2025 The Korean Academy of Stomatognathic Function and Occlusion.
©It is identical to Creative Commons Non-Commercial License.

prove occlusal relationships by guiding mandibular movements and increasing functional contacts.[4] In this case, a customized splint was fabricated with a buccal wall to limit mandibular deviation and prevent further displacement of the left condyle. This design compensated for surgical limitations, enhanced occlusal stability, and provided a favorable foundation for subsequent prosthetic treatment.

This case report describes the multidisciplinary management of a young patient with severe posttraumatic deformities, emphasizing the integration of digital implant planning and adjunctive occlusal splint therapy. It highlights the challenges of reestablishing stable occlusion after initial misalignment and demonstrates how combining digital technology with conservative occlusal management can yield predictable functional and esthetic outcomes.

Case Report

The patient was a 32-year-old male admitted to the emergency department after a pedestrian traffic accident, causing multiple systematic fractures including bilateral Le Fort I, II, and III fractures, as well as fractures of the mandibular symphysis, left condyle, and anterior maxilla in the maxillofacial area. Following multidisciplinary surgeries with prior internal fixation performed in other departments, he was referred to the dental department for intraoral reconstruction (Fig. 1). However, clinical and radiographic analysis showed that mandibular alignment had been achieved without regard for the original occlusion. The left mandibular segment was fixed in a medially and inferiorly tilted position, resulting in only single occlusal contact between the left maxillary and mandibular second molars (Fig. 2).

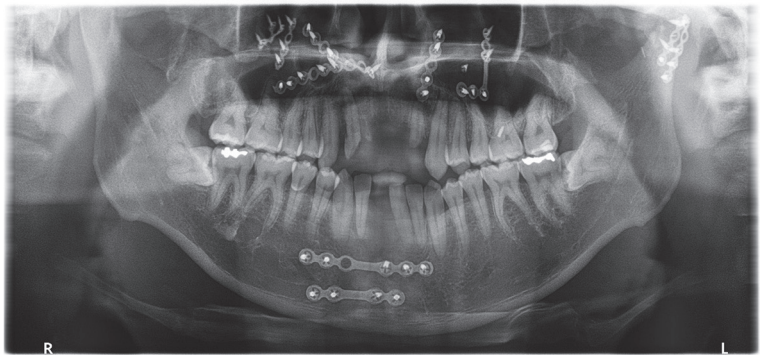

Fig. 1. This is the panoramic radiograph taken at the initial visit. The patient had already undergone reduction surgery in another department.

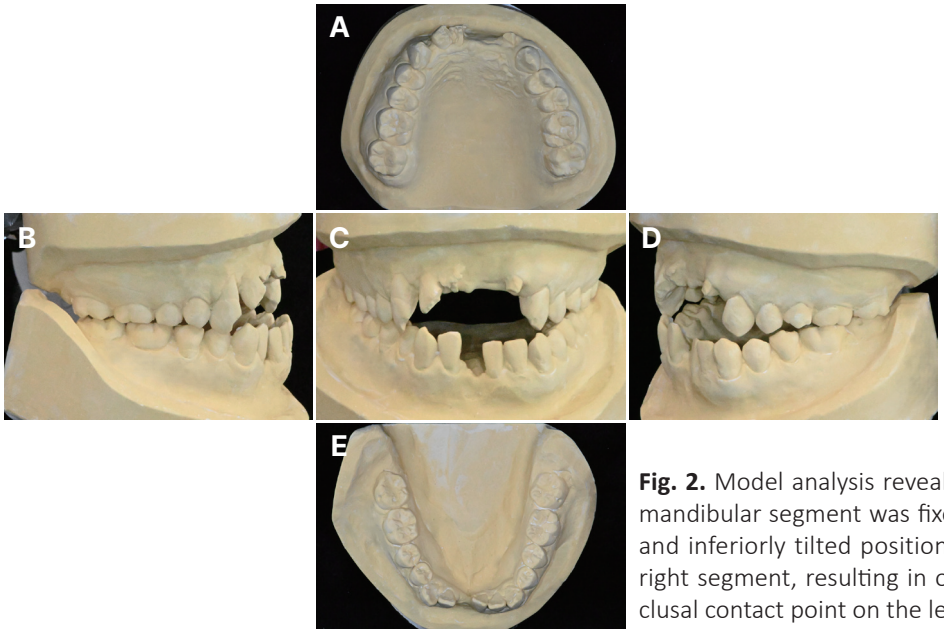

Fig. 2. Model analysis revealed that the left mandibular segment was fixed in a medially and inferiorly tilted position relative to the right segment, resulting in only a single occlusal contact point on the left side.

Radiographs also revealed displacement of the left condyle from the glenoid fossa, with fibrous adhesions restricting jaw function. Maximum interincisal opening was limited to 20 mm, and during mouth opening, the mandible deviated to the left. All eccentric movements were restricted, with near-complete limitation of rightward movement. Intraoral examination showed avulsion of the left maxillary and right mandibular central incisors, fractured remnants of other maxillary incisors, and external resorption with bone loss around the right maxillary canine.

Preliminary impressions were taken using individual trays due to limited mouth opening, and centric relation records were obtained. Diagnostic models were then mounted on a semi-adjustable articulator. (KaVo PROTARevo, KaVo Dental GmbH, Biberach, Germany) After consultation with oral and maxillofacial surgery, reoperation with open reduction was planned to reposition the mandible and improve occlusion. For anterior restorations, the left mandibular central incisor and the maxillary anterior segment from the right canine to the left lateral incisor were extracted. A removable flipper was used to replace the missing anterior teeth until definitive prosthetic restoration was performed.

Because no fractures were detected in the maxillary posterior region, the molar positions were considered unchanged from the pre-trauma state. On the mandibular model, the symphyseal area was sectioned to reproduce the injury, and intercuspation of both molars was verified against the maxilla. Each side was fixed individually on the articulator, then unified with a connecting base. This arrangement was regarded as the pre-trauma occlusal relationship, and a surgical wafer was fabricated accordingly (Ortho-Jet™ powder and Jet™ liquid, LANG, Chicago, USA) (Fig. 3). Surgery was carried out with wafer guidance and fixation using plates and SAS implants. However, functional recovery of occlusion was not achieved, likely due to fibrous adhesion of the condyle and muscle tension.

Although reoperation offered limited benefit, a specially designed occlusal splint was used to compensate for surgical limitations. As the left condyle had shifted after fracture and surgery, remodeling and stabilization were encouraged with splint therapy for about one year, six hours daily, with monthly adjustments to monitor progress and optimize function. The maxillary splint increased the vertical dimension by 4 mm and incorporated a 2-mm buccal wall in the left posterior region to guide the mandible rightward and reduce condylar displacement (Fig. 4). The thickness of the wall increased progressively as it approached the maxillary occlusal surface, creating an obliquely inclined plane slanting medially in the coronal view. The buccal wall was modified chairside by



Fig. 3. A surgical wafer was fabricated based on the presumed pre-trauma occlusal relationship.

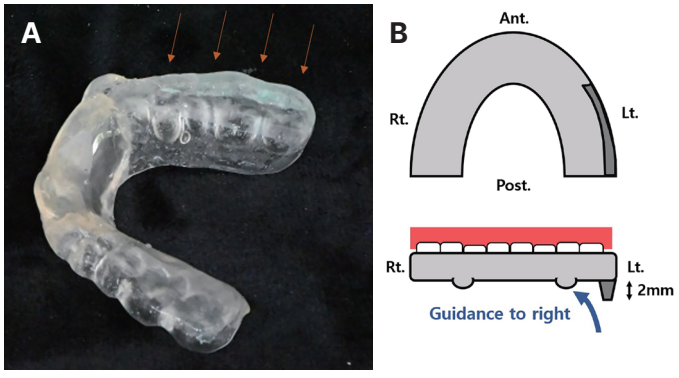

Fig. 4. A occlusal splint was fabricated. (A) The red arrow indicates the buccal wall, (B) This is a simple illustration of the splint design. A buccal wall approximately 2 mm in height was added to the splint in the left maxillary posterior region to restrict leftward deviation of mandible.

layering resin powder and liquid (Ortho-Jet™ powder and Jet™ liquid, LANG) directly in the patient's mouth, with adjustments made to ensure it did not interfere with mandibular movements during functional observation. With the splint, the maximum mouth opening improved from 20 to 32 mm. Radiographic evaluation revealed limited but improved mandibular movement, with a stable condylar position and evidence of condylar head remodeling (Fig. 5). Also, at maximum intercuspation, the number of occlusal contact points increased from 2 points on a single tooth before splint therapy to 10 points on 6 teeth at the end of treatment. New occlusal contacts developed across most teeth except the right molars and left first premolar, for which crown restoration was planned to establish proper contact (Fig. 6). In addition, eccentric movements were partially restored, except for right lateral movement. Based on this improved occlusion, prosthetic rehabilitation was planned: implants for missing anterior region (#13-22, 31, 41) and crowns for nonfunctional (#16, 17, 23-25) or uneven teeth (#32, 33, 42, 43), including the left canine and second premolar to improve occlusal stability.

Severe vertical and horizontal bone loss was noted in the maxillary anterior region. Given the patient's young age, implant restoration was planned, with emphasis on a screw- and cement-retained prostheses (SCRP) design to ensure long-term prognosis. To realize precise implant positioning and angulation essential for the SCRP concept in the anterior region, digital surgery was performed using a digital guide. (OneGuide, Osstem, Seoul, Korea) The implant plan was established in design software (Implant Studio, 3Shape, Copenhagen, Denmark) based on intraoral scanning data (TRIOS3, 3Shape) and CBCT images (Fig. 7). Internal type fixtures (TS III system, Osstem) were placed at #11, 13, 22, and 31 (Ø3.5 × 10

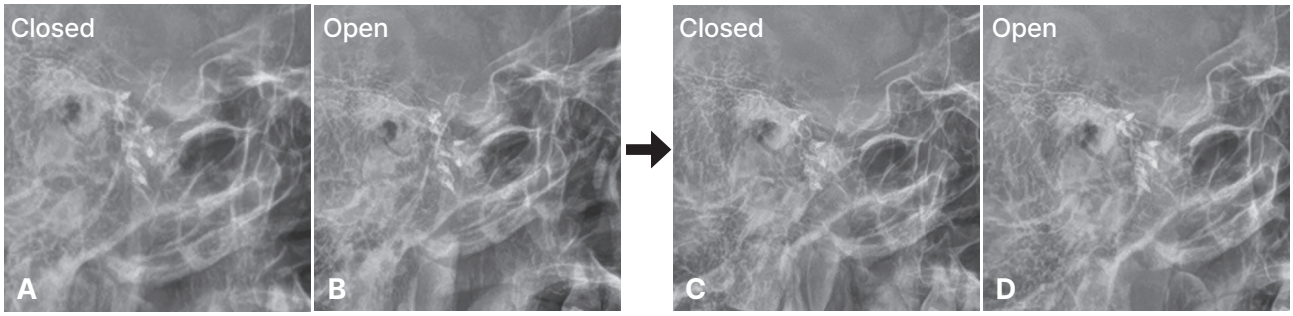

Fig. 5. Cephalometric radiographs showing improved condylar stability. (A) Closed left condyle before splint therapy, (B) Open left condyle before the therapy, (C) Closed left condyle after the therapy, (D) Open left condyle after the therapy. Remodeling of the condylar head morphology and stability within the condyle were confirmed.

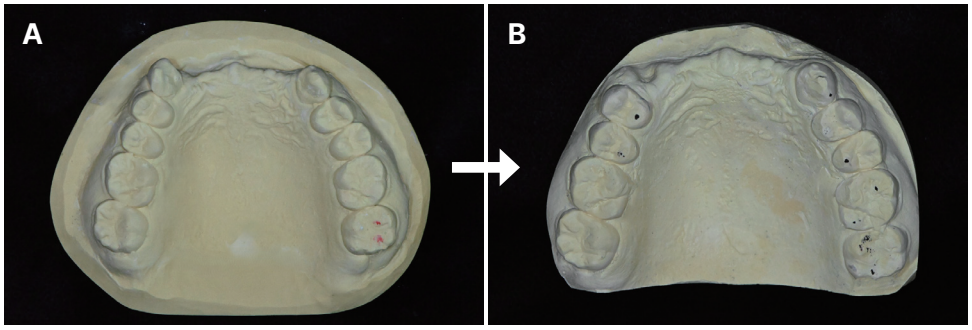

Fig. 6. New occlusal contacts developed across most teeth except the right molars and left first premolar. Occlusal records were marked on the model with reference to the bite registration. (A) Before splint therapy, (B) After splint therapy.

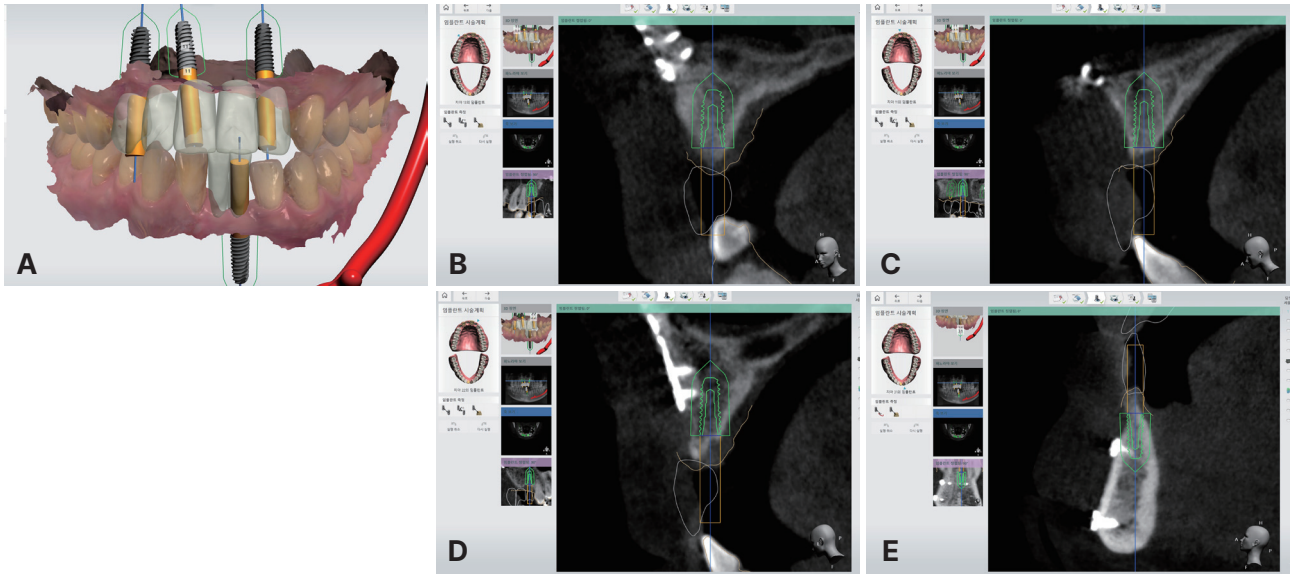

Fig. 7. Digital guides (OneGuide, Osstem) were designed through CT and scan image. (A) Prosthodontic design, (B) #13i position and angulation in CT, (C) #11i position and angulation in CT, (D) #22i position and angulation in CT, (E) #31i position and angulation in CT.

mm for #11i, 22i, 31i and Ø4.0 × 10 mm for #13i). Guided bone regeneration (Bio-Oss & Bio-Gide, Geistlich, Luzern, Swiss) was required due to buccal exposure at #31.

At three months, osseointegration was confirmed. A pick-up impression was taken using Polyether (Soft Monophase, 3M ESPE, Neuss, Germany), and custom abutments with provisional prostheses were fabricated digitally (Fig. 8) and delivered using a non-eugenol zinc-oxide cement (Premier, Premier, Lancaster, USA). Preparation of the natural teeth (#16, 17, 23, 24, 25, 32, 33, 42, 43) was also completed as planned. The occlusion was established to provide group function during protrusive and left lateral movement to distribute lateral forces. After two months, the provisional prostheses demonstrated favorable esthetic and functional stability, and fabrication of the final prosthesis was planned (Fig. 9).

An abutment-level impression was taken for both implants and abutment teeth using a two-step putty-wash technique with silicone putty (Exafine, GC, Tokyo, Japan) and light-bodied addition silicone (Imprint™ II Garant, 3M ESPE) (Fig. 10). As multiple maxillary teeth were missing or prepared, the occlu-

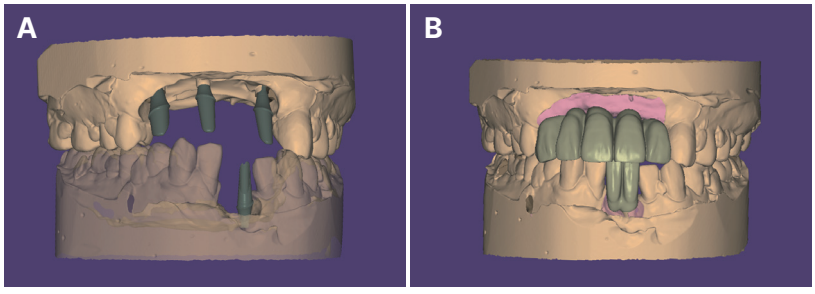

Fig. 8. Custom abutments with provisional prostheses were fabricated digitally using CAD software (exocad, exocad GmbH). (A) Custom abutments, (B) Provisional prostheses.



Fig. 9. The provisional prostheses were observed for two months, showing favorable functional and esthetic outcomes.

sal plane was verified with the provisional prostheses in place, ensuring parallelism to the Ala-tragus and interpupillary lines, followed by a facebow transfer. Cross mounting of the provisional and working casts was performed to accurately transfer occlusal relationships and dimensions.

The final prostheses were digitally designed by CAD software (exocad, exocad GmbH, Darmstadt, Germany) (Fig. 11) and milled from monolithic zirconia. Right lateral movement was completely restricted and left lateral movement was guided by the canine and premolars, while protrusive movement was evenly guided by the anterior teeth. Also, a shallow anterior guidance was established due to the shallow overbite (Fig. 12). Screw holes remained accessible on all implant restorations after cementation, ensuring retrievability of the maxillary prosthesis (Fig. 13). Regular follow-ups included supportive periodontal therapy for hygiene maintenance, and the restorations have remained stable without complications to date, with no prosthetic mobility, screw loosening, or occlusal instability observed (Fig. 14).

Discussion

According to Misch's classification, removable prostheses are generally recommended in severe bone loss because they compensate for tissue deficiency and allow easier hygiene maintenance.[2] However, in this patient, despite being categorized as high risk for implant rehabilitation due to vertical and horizontal ridge deficiency with only moderate width and height,[3] fixed implant-supported prostheses were considered. This decision reflected the patient's young age and psychological preference for fixed restorations rather than removable options. Although implant treatment in high-risk cases involves several prosthetic challenges such as crown elongation and hypercontouring,[2,6] these were addressed through strategic implant positioning and prosthetic design,

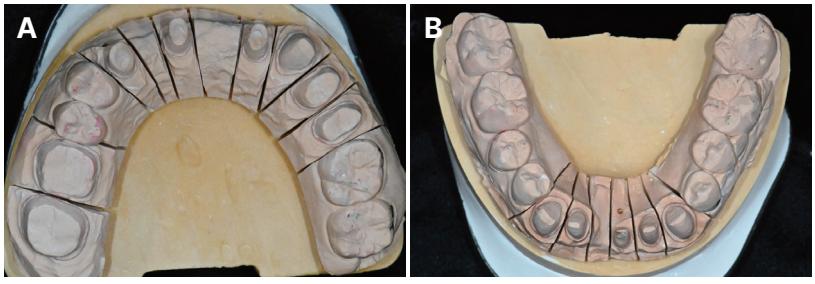

Fig. 10. A master cast was fabricated from the abutment-level impression for both the implants and the abutment teeth. (A) master cast for upper, (B) master cast for lower.

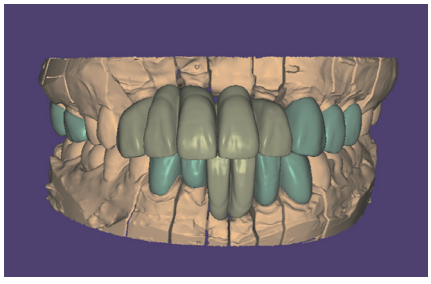

Fig. 11. For the fabrication of the final prostheses, the provisional prostheses model and master cast were scanned and designed using CAD software (exocad, exocad GmbH).



Fig. 12. Eccentric movements are demonstrated after final prosthetic restoration. (A) Right lateral movement, (B) Protrusive movement, (C) Left lateral movement.



Fig. 13. Occlusion of zirconia prostheses were adjusted to replicate the provisional.

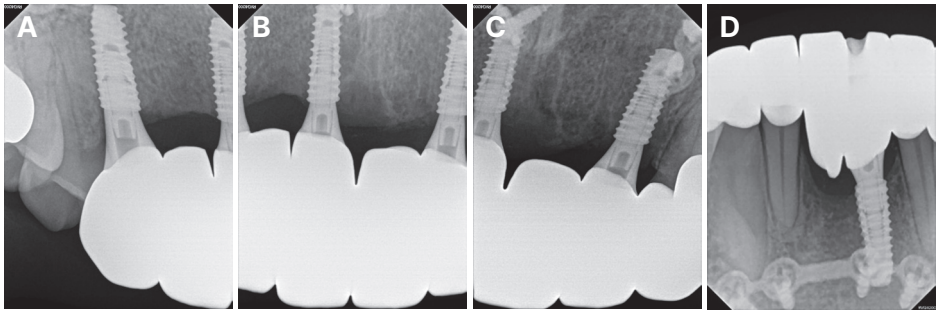

Fig. 14. Radiographs demonstrate successful prosthesis placement/connection. The restoration has been well maintained without any complications to date. (A) #13i, (B) #11i, (C) 22i, (D) #31i.

with retrievability emphasized to support long-term maintenance. Importantly, the use of a digital surgical guide facilitated precise placement, allowing screw access holes to emerge on the palatal side.

Nevertheless, post-traumatic maxillary atrophy contributed to further limitations in prosthetic design. Horizontal bone resorption induced an anterior crossbite tendency, requiring a cantilevered prosthetic approach to achieve improved esthetics and function.[7] To mitigate biomechanical risks, multiple implants were splinted and the anterior-posterior distribution was maximized.[6] However, arch constriction in the premaxilla still restricted inter-implant spacing and compromised embrasure form.

Another notable aspect of this case was the role of occlusal splint therapy. Splints are well-documented to reduce muscular tension, stabilize occlusion, and prevent intra-articular deterioration.[4,8] It does not reposition the condyle but allows functional adaptation by forming a pseudodisc in the posterior attachment area.[9] Several studies have reported that splint therapy promotes symmetrical masticatory muscle contraction and contributes to remodeling and positional changes of the condyle and articular eminence, thereby improving mandibular asymmetry.[10,11] In cases such as this, where the condyles exhibit asymmetry in position and morphology, achieving improved balance can help restore harmony within

the masticatory system, encompassing the temporomandibular joints, muscles, and teeth. Over the course of one year, splint therapy enhanced mouth opening, increased the number of occlusal contacts, and stabilized condylar function, thereby facilitating subsequent prosthetic reconstruction.

Unilateral condylar adhesions or non-reducing disc displacement often restrict contralateral mandibular movements.[12] A customized splint with a buccal wall was specifically designed to control mandibular deviation and prevent further displacement of the left condyle, promoting favorable mandibular movement and preventing relapse. Although rightward excursion remained limited, improvements in anterior and leftward movements provided a more stable occlusal foundation.

Splint therapy helped improve functional stability by addressing postoperative issues that may arise from inadequate symphyseal refixation, insufficient condylar management, muscle-induced relapse, and limited intermaxillary fixation. Reoperation is generally reserved for severe malocclusion or significant temporomandibular dysfunction.[13] When discrepancies are mild and surgical risks are high, occlusal splint therapy represents a viable conservative alternative.[14] Moreover, evidence suggests that combining intermaxillary fixation with splint therapy can further enhance occlusal stability and functional recovery in selected cases.[15]

Thus, this case underscores the value of combining digital implant planning with adjunctive occlusal splint therapy to overcome surgical limitations and achieve predictable outcomes. Conservative splint therapy, particularly when customized to control mandibular position, can provide functional improvements that support long-term prosthetic success in patients with complex post-traumatic deformities.

Conclusion

Functional and esthetic rehabilitation of severe post-traumatic deformities was achieved through digitally assisted, implant-supported prostheses. Accurate implant positioning ensured esthetics and preserved future removability, while splint therapy stabilized occlusion and TMJ function, compensating for initial surgical limitations. This case underscores the importance of digital technology and conservative adjuncts in achieving predictable outcomes in complex maxillofacial trauma. Long-term follow-up and regular implant maintenance remain essential for sustained success.

ORCID

Jeong-in Shin https://orcid.org/0009-0009-0422-1998
Jong-jin Kim https://orcid.org/0000-0003-1815-3294
Joohee Lee https://orcid.org/0000-0001-5644-0126
Jin Baik https://orcid.org/0000-0002-3622-3113
Hyunsuk Cha https://orcid.org/0000-0001-5164-5181

References

1. Louis P, Management of panfacial fractures. In: Miloro M, Larsen PE, Ghali GE, Waite PD, editors. Peterson's principles of oral and maxillofacial surgery. Berlin; Springer International Publishing; 2022. p. 849-70.
2. Misch CE, Judy KW. Classification of partially edentulous arches for implant dentistry. Int J Oral Implantol 1987;4:7-13.
3. Juodzbalys G, Kubilius M. Clinical and radiological classification of the jawbone anatomy in endosseous dental implant treatment. J Oral Maxillofac Res 2013;4:e2.
4. Albagieh H, Alomran I, Binakresh A, Alhatarisha N, Almeteb M, Khalaf Y, Alqublan A, Alqahatany M. Occlusal splints-types and effectiveness in temporomandibular disorder management. Saudi Dent J 2023;35:70-9.
5. Khalaf K, Kheder W, El-Kishawi M, AlQahtani HA, Ghiasi FS, Alabdulkareem MN, Zahiri AN, Rahmani NI. The role of prosthetic, orthodontic and implant-supported rehabilitation in the management of secondary malocclusion to maxillofacial trauma - A systematic review. Saudi Dent J 2021;33:177-83.
6. Gowd MS, Shankar T, Ranjan R, Singh A. Prosthetic consideration in implant-supported prosthesis: a review of literature. J Int Soc Prev Community

Dent 2017;7 Suppl 1:S1-S7.
7. Alsi SA, Deshpande S, Pande N. Clinical outcomes of implant-supported prosthetic rehabilitation of severely atrophic maxilla: A systematic review. J Indian Prosthodont Soc 2023;23:335-46.
8. Tăut M, Barbur I, Hedeșiu M, Ban A, Leucuța D, Negucioiu M, Buduru SD, Ilea A. Condylar Remodeling and Skeletal Changes Following Occlusal Splint and Manual Therapy: A Cone Beam Computed Tomography Study in Temporomandibular Disorders. J Clin Med 2024;13:5567.
9. Lee GH, Lee JH, Moon DN, Lee SM. Protocols for orthodontic treatment of patients with temporomandibular joint disorders. Am J Orthod Dentofacial Orthop 2021;159:373-88.
10. Ferrario VF, Sforza C, Tartaglia GM, Dellavia C. Immediate effect of a stabilization splint on masticatory muscle activity in temporomandibular disorder patients. J Oral Rehabil 2002;29:810-5.
11. Musa M, Awad R, Izeldin S, Zhao Y, Wu H, Wang L, Al-Hadad SA, Saif BS, Ahmed MMS, Chen X. Quantitative and qualitative condylar changes following stabilization splint therapy in patients with temporomandibular joint disorders with and without skeletal lateral mandibular asymmetry: a cone beam computed tomographic study. BMC Oral Health 2024;24:363.
12. Pérez del Palomar A, Doblaré M. Influence of unilateral disc displacement on the stress response of the temporomandibular joint discs during opening and mastication. J Anat 2007;211:453-63.
13. Watanabe T, Hirota M. Revision surgery for malocclusion after open reduction of mandibular fracture: a case report. J Korean Assoc Oral Maxillofac Surg 2025;51:54-8.
14. Hussein MA, Besher A, Saad MA, Wilson AM. Versatility of Hard Occlusal Splints in Optimizing Outcomes in Patients with Old Pan-facial Fractures. Plast Reconstr Surg Glob Open 2021;9:e3855.
15. Kaya D, Kocadereli I, Akcan CA, Konas E, Mavili ME. Use of Acrylic Occlusal Splint and Direct Bonded Brackets for Intermaxillary Fixation in the Treatment of Unilateral Parasymphyseal and Condylar Fractures: A Case Report. Clin Dent Res 2013;37:46-50.

범안면 외상 환자에서 교합 안정장치를 활용한 전치부 임플란트 수복 증례

신정인[1] 전공의, **김종진**[1] 교수, **이주희**[1,2] 교수, **백진**[1] 교수, **차현석**[1,2*] 교수

[1]서울아산병원 치과보철과

[2]울산대학교 의과대학

본 증례는 교통사고로 전안면 골절과 전치부 상실을 동반한 32세 남환의 보철 수복 과정을 보고한다. 초기 고정 수술 후에도 부정교합과 측두하악관절 변위가 잔존해 재수술을 시행했으나 섬유성 유착으로 교합 회복은 제한적이었다. 이에 1년간 교합 스플린트 치료로 관절 안정과 교합 개선을 얻은 뒤, 디지털 계획 기반으로 전치부 고정성 임플란트 보철물로 수복하였다. 본 증례의 특징은 심한 골 결손 상황에서 환자의 연령과 요구를 고려해 고정성을 유지하면서도 탈착 가능한 나사-시멘트 유지형 보철을 적용하였으며 또한 장기간의 스플린트 치료를 통해 교합 개선과 턱관절 안정성이 개선되었다. 따라서 본 증례는 외상 후 교합 불일치와 골 결손 환자에서 디지털 기술과 보조적 교합치료를 병행함으로써 기능적·심미적 회복을 달성하였기에 보고하고자 한다.

(구강회복응용과학지 2025;41(4):344-53)

주요어: 범안면 골절; 측두하악관절 변위; 교합 안정장치; 탈착 가능성; 나사-시멘트 유지형 임플란트; 디지털 임플란트 계획

*교신저자: 차현석

(05505)서울특별시 송파구 올림픽로43길 88 서울아산병원 신관 치과보철과

Tel: 02-3010-3847 | Fax: 02-3010-6967 | E-mail: chahyunsuk@hanmail.net

접수일: 2025년 10월 1일 | 수정일: 2025년 10월 15일 | 채택일: 2025년 10월 17일