https://doi.org/10.14368/jdras.2026.42.1.72
ISSN 2384-4353 eISSN 2384-4272

Case Report

Quantitative monitoring of epulis fissuratum using a uniform lip retractor: a case report

Che-I Hyun, Kwi-Dug Yun*, Chan Park, Woo-Hyung Jang
Department of Prosthodontics, School of Dentistry, Chonnam National University, Gwangju, Republic of Korea

Epulis fissuratum requires effective management to ensure a stable foundation for denture fabrication. While tissue conditioners are commonly used for treatment, monitoring the healing process typically relies on subjective visual inspection. Furthermore, objective assessment using intraoral scanners is challenging due to the high mobility of vestibular tissues. To address this limitation, a custom-made, patient-specific lip retractor was utilized to standardize the scanning procedure. In this case, a 75-year-old patient presented with mandibular anterior epulis fissuratum. The lip retractor was fabricated to minimize tissue displacement, and its precision was verified with a minimal RMS deviation of 88.5 μm. Weekly superimposition of scans successfully quantified the reduction in lesion volume. This technique allowed the clinician to transition from subjective inspection to objective, quantitative monitoring of soft tissue healing, confirming the efficacy of the treatment. **(J Dent Rehabil Appl Sci 2026;42(1):72-8)**

Key words: gingival hyperplasia; imaging, three-dimensional; mouth, edentulous

Introduction

Epulis fissuratum, also known as denture-induced fibrous hyperplasia, is a reactive lesion caused by chronic irritation from ill-fitting prostheses. Although reported prevalence varies widely (13% to 68%), it is consistently observed in long-term denture wearers, particularly in the anterior region of the jaw.[1,2]

Standard management strategies range from conservative reduction using tissue conditioners to surgical excision combined with vestibuloplasty for larger lesions.[3,4] However, even after surgical intervention, managing the healing process and residual inflammation with tissue conditioners is crucial to ensure a stable foundation for the prosthesis. Specifically, the denture borders should be relined with a tissue conditioner to form rounded margins, which prevents loss of vestibular depth and facilitates soft tissue recovery.[5] The healing process generally requires a period of approximately 4 - 8 weeks with/or surgical intervention, during which the tissue conditioner is exchanged weekly.[6] A major limitation of this approach is the reliance on subjective visual inspection to determine the optimal timing for definitive prosthetic rehabilitation. Visual assessment often fails to detect minute volumetric changes, making it difficult to distinguish between active tissue regression and the stabilization phase where no further shrinkage occurs.

Longitudinal monitoring using intraoral scanners offers a solution but is complicated by the mobility of vestibular tissues.[7] To accommodate the scanner tip, the lips and cheeks must be retracted. However, variations in retraction force can distort the mobile

*Correspondence to: Kwi-Dug Yun
Professor, Department of Prosthodontics, School of Dentistry, Chonnam National University, 33 Yongbong-ro, Buk-gu, Gwangju, 61186, Republic of Korea
Tel: +82-62-530-5638, Fax: +82-62-530-5639, E-mail: ykd@chonnam.ac.kr
Received: January 12, 2026/Last Revision: January 29, 2026/Accepted: February 6, 2026

Copyright© 2026 The Korean Academy of Stomatognathic Function and Occlusion.
©It is identical to Creative Commons Non-Commercial License.

mucosa. These morphological changes during the scanning process frequently lead to stitching errors. This issue is particularly pronounced in edentulous areas and the mucogingival junction. This clinical report describes a custom-made, patient-specific lip retractor designed to overcome this challenge. The device was validated for precision and subsequently applied to objectively quantify the regression of epulis fissuratum, enabling a data-driven assessment of soft tissue healing.

Case Report

A 75-year-old male patient presented with discomfort in the mandibular anterior region. His medical history included hypertension, diabetes, and the use of antiplatelet medication. Clinical examination revealed a mobile, edematous labial fold diagnosed as epulis fissuratum in the mandibular vestibule (Fig. 1). The patient had been wearing complete dentures fabricated 10 years prior, which exhibited excessive occlusal wear and compromised retention and stability. Significant mandibular ridge resorption was observed (Fig. 2); therefore, a mandibular two-implant overdenture and a maxillary complete denture were planned. After implant insertion, the provisional denture on the mandible would be periodically relined with a tissue conditioner to reduce the epulis fissuratum and reshape the vestibule. Initial management included the delivery of a provisional denture and the placement of two implants in the anterior mandible.

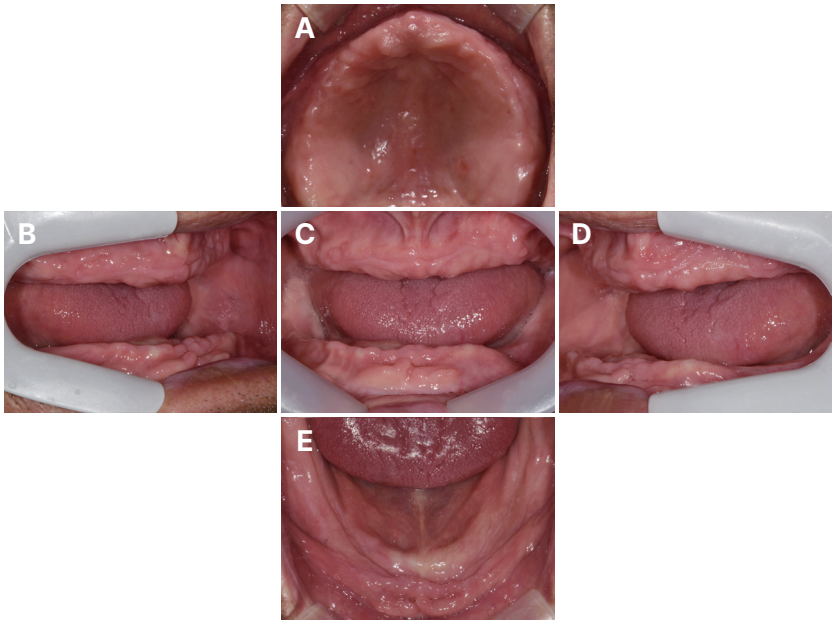

Fig. 1. Pretreatment intraoral photograph showing the epulis fissuratum in the anterior mandible. (A) Maxillary occlusal view, (B) Right lateral view, (C) Frontal view, (D) Left lateral view, (E) Mandibular occlusal view.

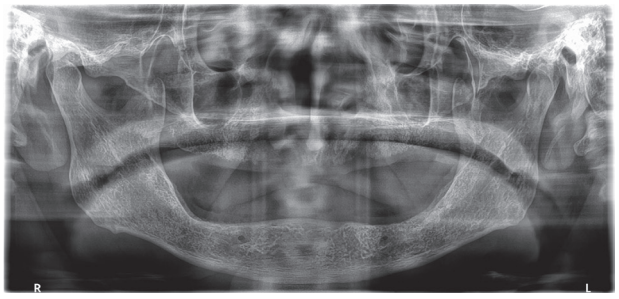

Fig. 2. Pretreatment panoramic radiograph.

A provisional denture was fabricated and duplicated for a radiographic stent. Two dental implants (Anyone; MegaGen, Daegu, Korea) 3.5 mm in diameter and 10.0 mm in length were placed parallel to each other within the interforaminal region. Following the surgery, conservative soft tissue management was initiated using the tissue conditioner (COE-COMFORT; GC Corp, Tokyo, Japan). The intaglio surface and the labial border of the mandibular provisional denture was periodically relined to gradually reshape the epulis fissuratum (Fig. 3). The powder-to-liquid (P/L) ratio of the tissue conditioner was adjusted to a higher viscosity to avoid replicating the irregular morphology of the lesion close to the labial border. This precise control of material flow facilitated the formation of a rounded border.

To objectively monitor the soft tissue response, a standardized retraction device comprising three components was fabricated. For the mandibular component, a silicone putty index (EXAFINE Putty Type; GC Corp) was formed along the anterior vestibule to define the optimal vestibular extension. Self-curing resin (Ortho-Jet; Lang Dental, Wheeling, USA) was adapted against this index to fabricate an anterior retraction plate (Fig. 4A). This plate was connected bilaterally to the mandibular recording base and occlusal rims to ensure stability. For the maxillary component, the patient's provisional denture was scanned extraorally. An anterior window was designed to facilitate intraoral scanner access using CAD software (Meshmixer; Autodesk, San Rafael, USA) and fabricated using a 3D-printing resin (SG-100; Graphy, Seoul, Korea). Intraoral positioning was stabilized by injecting bite registration material (O-Bite; DMG, Hamburg, Germany) between the components, establishing a closed-mouth position for uniform lower lip retraction (Fig. 4B, 4C). Prior to longitudinal monitoring, the precision of the scanning method was verified. Three consecutive scans were acquired using the custom-made lip retractor. The healing

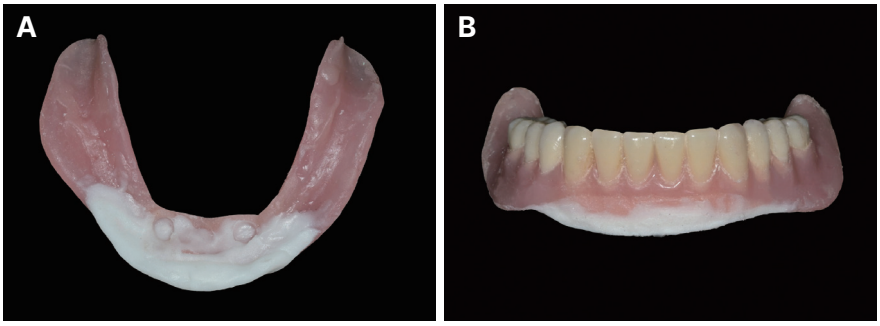

Fig. 3. Conservative management of epulis fissuratum using a provisional denture. (A) The intaglio surface relined with tissue conditioner, (B) Frontal view showing the rounded borders.

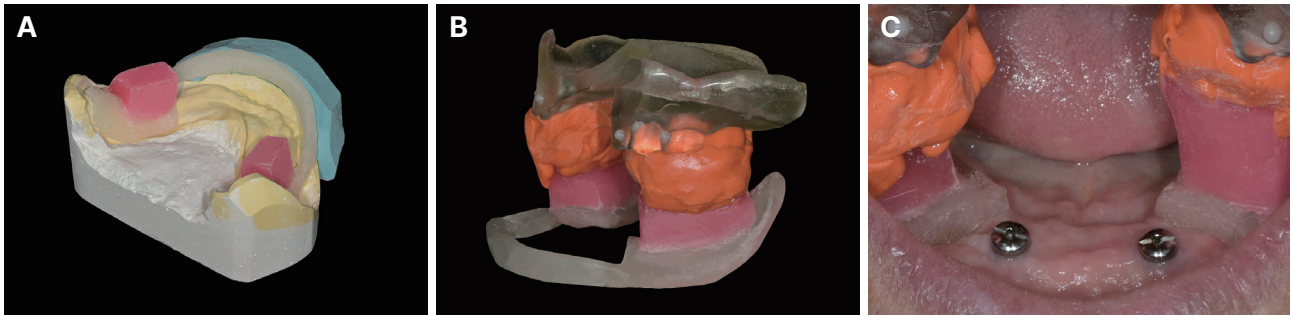

Fig. 4. Design and application of the custom-made retractor. (A) The mandibular anterior retraction plate fabricated with self-curing resin, (B) The assembled device with the maxillary 3D-printed component and bite registration material, (C) Intraoral photograph of the device in position, ensuring standardized retraction of the lower lip in a closed-mouth position.

abutments served as fixed reference markers for the alignment of the scan data. The datasets were superimposed using inspection software (Geomagic Control X; 3D Systems, Rock Hill, USA). The device demonstrated a high level of precision with a mean Root Mean Square (RMS) deviation of 88.5 μm and standard deviation (SD) of 88.1 μm, indicating sufficient reproducibility for the subsequent analyses (Table 1).

Table 1. Precision analysis of the scanning method based on three consecutive scans using the uniform lip retractor

Comparison pair	RMS deviation (μm)	SD (μm)
Scan 1 – Scan 2	68.9	68.7
Scan 1 – Scan 3	100.8	100.1
Scan 2 – Scan 3	95.7	95.4
Mean	88.5	88.1

RMS, root mean square; SD, standard deviation.

Validating the custom-made lip retractor justified a monitoring protocol with 10-day intervals to capture objective morphological data. Serial scans obtained with the device were superimposed using the healing abutments as fixed reference points. Dimensional changes were quantified by isolating the anterior soft tissue region of interest (ROI) and converting it into a solid mesh (Fig. 5). The quantitative analysis demonstrated a progressive reduction in lesion volume from a baseline of 1698.0mm^3 to 1506.8 mm^3 (88.7% of baseline) at day 10 and 1397.4mm^3 (82.3% of baseline) at day 20. The rate of reduction diminished in the latter phase, indicating a plateau in tissue healing. This stabilization of volumetric values suggested that inflammation resolution and soft tissue regression had been achieved, providing a rationale for excision of residual tissue and definitive denture fabrication (Fig. 6). One month following the surgical excision, once stable soft tissue healing

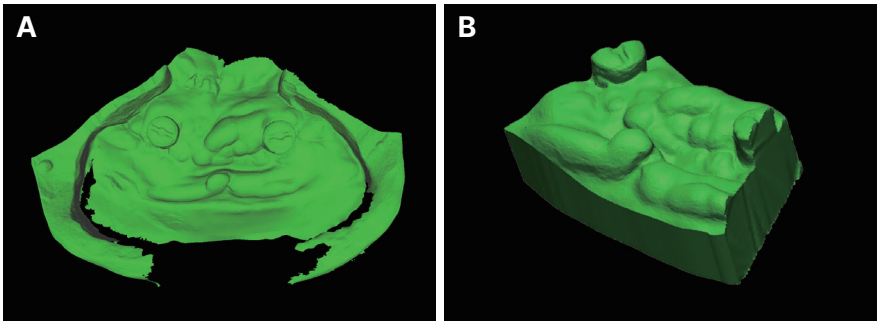

Fig. 5. Process of volumetric analysis. (A) The full scan range obtained from the intraoral scanner, (B) The selected region of interest (ROI) including the epulis fissuratum, converted into a solid mesh to calculate volume changes.

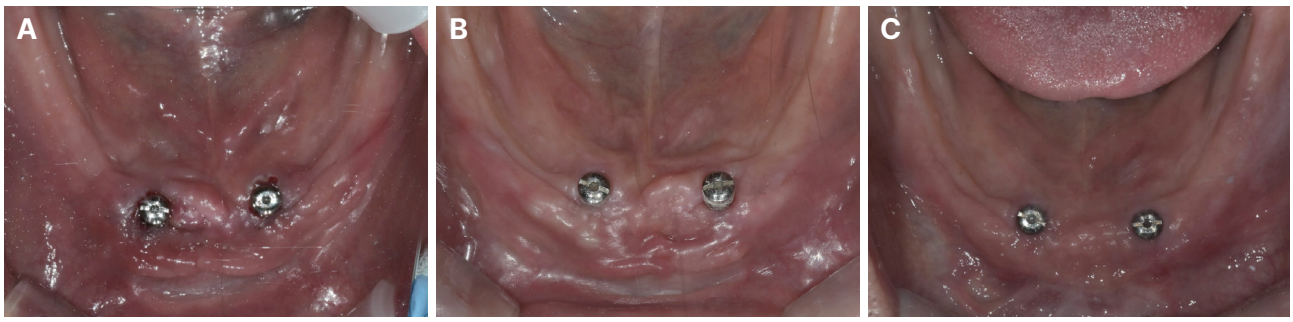

Fig. 6. Intraoral photographs showing clinical monitoring of the healing process (mandibular occlusal view). (A) Clinical view obtained 7 days after implant surgery, (B) Follow-up view taken 17 days after, (C) Final view taken 27 days after.

was observed, fabrication of the definitive prostheses was initiated. Maxillary complete denture and a mandibular implant overdenture using locator attachments (Meg-Rhein; MegaGen) was delivered (Fig. 7). During the follow-up examinations, the patient expressed satisfaction with the enhanced retention and stability of the mandibular definitive prosthesis. He reported that the previous mobility and functional discomfort during mastication have been eliminated. Furthermore, the resolution of chronic pain due to the epulis fissuratum contributed to the clinical success. Clinical assessments demonstrated stable periimplant bone levels, and no significant complication were observed.

Discussion

In this patient, prolonged denture use without regular maintenance resulted in severe mandibular ridge resorption and the development of epulis fissuratum due to chronic irritation from sharp, overextended denture flanges. Consequently, conservative treatment with a tissue conditioner was prioritized over immediate surgical excision as a strategic, staged clinical approach. Mekayssi et al.[8] emphasized that rounded denture borders with tissue conditioner promote physiologic reshaping and lesion regression. Pre-surgical conditioning significantly reduced the lesion volume, eliminating the need for invasive grafting. Consequently, a conservative excision relying on secondary epithelialization was chosen over free gingival grafts to avoid donor site morbidity. To compensate for tissue rebound, an extended resection was performed, and the provisional denture functioned as a vestibuloplasty splint. Although this protocol required more frequent visits, it effectively minimized surgical trauma and established a stable foundation for the definitive prosthesis.

The primary challenge in applying digital workflows to edentulous patients lies in capturing the mobile vestibular mucosa. Unlike attached gingiva or teeth, the vestibule is highly susceptible to displacement caused by retractor pressure or muscle movement, which often leads to scanning artifacts and stitching errors. While intraoral scanning has become widely used in fixed prosthodontics, these anatomical limitations have hindered its reliable application in removable prosthodontics. Cerghizan et al.[9] highlighted that intraoral scanning of the edentulous mandible remains technically demanding due to limited attached gingiva and mucosal mobility, which often compromises scan precision.

To address this, the customized retractor was designed not merely to retract the lips but to minimize vestibular displacement by establishing a standardized closed-mouth position. To ensure consistent positioning and minimize operator variability, the device was indexed using a bite registration material, and the same bite index was repositioned for each of the three repeated scans performed at the same appointment. The mean RMS deviation observed in our trial was 88.5 μm. Given that the accuracy of intraoral scans on edentulous ridges typically ranges from 300 to 500 μm due to mucosal mobility and

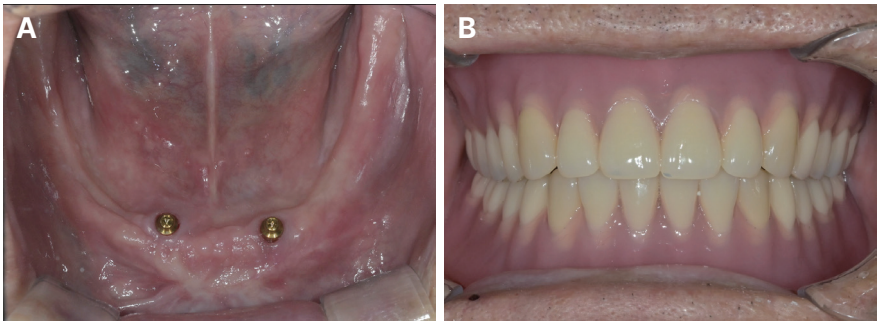

Fig. 7. Intraoral photographs after delivery of definitive prostheses. (A) Mandibular occlusal view showing the locator attachments connected to the implants, (B) Frontal view of the maxillary complete denture and mandibular implant overdenture in occlusion.

compressibility,[10] this result confirms that the retractor effectively stabilized the highly mobile vestibular tissues to a clinically acceptable level.

However, this technique presents challenges regarding workflow efficiency and structural integrity. The fabrication of a customized retractor requires additional chairside and laboratory time compared to conventional retractors. Additionally, the use of thermoplastic wax and a resin wing connection poses a potential risk of deformation or fracture. In this study, this risk was minimized by the rigid stabilization provided by the bite registration material and the passive nature of the closed-mouth scanning position. Nevertheless, future iterations could overcome these structural limitations by employing computer-aided-design and manufacturing (CAD/CAM) workflows. For cases requiring longitudinal precision or reproducibility across multiple visits, this specific device offers a level of accuracy that conventional methods cannot match.

Conclusion

The patient-specific lip retractor effectively addresses the inherent instability of vestibular tissues during intraoral scanning. By eliminating motion-induced stitching errors, this device stabilizes the mobile mucosa, thereby expanding the feasible range of digital impressions into the deep vestibule. Furthermore, this precise monitoring capability validated the efficacy of the conservative relining protocol, demonstrating that pre-surgical tissue conditioning can successfully reduce lesion volume and minimize surgical invasiveness. While demonstrated here for epulis fissuratum, this combined workflow holds broader potential for any clinical scenario requiring accurate soft tissue management.

ORCID

Che-I Hyun https://orcid.org/0009-0009-3861-4896
Kwi-Dug Yun https://orcid.org/0000-0002-2965-3967
Chan Park https://orcid.org/0000-0001-5729-5127
Woo-Hyung Jang https://orcid.org/0000-0001-8077-6877

References

1. Gu W, Li S, Hu S, Yao Y, Jiang X, Kreher D, Schmalz G, Jiang L, Meng W. Epulis: A Narrative Review of Epidemiology, Clinical Features, Pathogenesis, and Management. Oral Health Prev Dent 2025;23:507-24.
2. Canger EM, Celenk P, Kayipmaz S. Denture-related hyperplasia: a clinical study of a Turkish population group. Braz Dent J 2009;20:243-8.
3. Eversole LR. Clinical outline of oral pathology: diagnosis and treatment. 4th ed. Shelton; PMPH-USA; 2011. p. 185.
4. Lomelí-Martínez SM, González-Gómez LA, Martínez-González EJ, Alarcón-Sánchez MA, Alcaraz-Baturoni FJ, Robles-García MA, Mehta V, Heboyan A. Integral surgical management of epulis fissuratum using conventional excision and free gingival graft: a case report. J Surg Case Rep 2025 Nov 27;2025(11):rjaf943. doi: 10.1093/jscr/rjaf943.
5. Jeong CM, Huh JB, Lee SH. Relining - basic to troubleshooting. Seoul; Daehan-Narae Publishing Inc; 2023. p. 45-9.
6. Widad EG, Nadia M, Jihane SH. Prosthetic management of an epulis fissuratum with simple conditioning tissue: a case report. Int J Surg Case Rep 2024;122:110130.
7. Chebib N, Imamura Y, El Osta N, Srinivasan M, Müller F, Maniewicz S. Fit and retention of complete denture bases: Part II - conventional impressions versus digital scans: a clinical controlled crossover study. J Prosthet Dent 2024;131:618-25.
8. Mekayssi R, Taleb B, Merzouk N, Benfdil F. The prosthetic management of a case of epulis fissuratum by a novel technique. Odovtos Int J Dent Sci 2020;23:27-32.
9. Cerghizan D, Jánosi KM, Farcas A, Bojan MM, Muntean MH, Nechiti AAM, Mureşan IÉ, Pop SI, Marada G. Accuracy of analog and digital full-arch mandibular impressions: in vitro and in vivo evaluation. Diagnostics 2025;15:2077.
10. Srivastava G, Padhiary SK, Mohanty N, Molinero-Mourelle P, Chebib N. Accuracy of intraoral scanner for recording completely edentulous arches-a systematic review. Dent J 2023;11:241.

균일 구순 견인기를 이용한 치은열성비대의 정량적 치유 평가: 증례 보고

현채이 전공의, **윤귀덕*** 교수, **박찬** 부교수, **장우형** 조교수
전남대학교 치의학전문대학원 치과보철학교실

치은열성비대의 치유 과정은 주로 주관적인 관찰에 의존하며, 가동성 있는 전정 조직의 특성상 구강 스캐너를 이용한 객관적인 평가가 어렵다. 본 증례는 이를 극복하고자 환자 맞춤형 균일 구순 견인기를 제작하여 반복적인 스캔 시에도 일정한 리트렉션을 통하여 중첩이 가능하도록 하였다. 적용 결과, 평균 RMS 88.5 μm (표준편차 88.1 μm)의 높은 스캔 정밀도를 보였으며, 주간 스캔 데이터의 중첩을 통해 조직조정재를 이용한 치은열성비대 병소의 부피 감소를 정량적으로 평가하였다. 본 기법은 연조직 치유 과정을 주관적 관찰에서 객관적, 정량적 모니터링으로 전환하여 치료 효과를 입증하는 유용한 방법임을 시사한다.

(구강회복응용과학지 2026;42(1):72-8)

주요어: 치은 증식; 3차원 영상; 무치악

*교신저자: 윤귀덕
(61186)광주광역시 북구 용봉로 33, 전남대학교 치의학전문대학원 치과보철학교실
Tel: 062-530-5638 | Fax: 062-530-5639 | E-mail: ykd@chonnam.ac.kr
접수일: 2026년 1월 12일 | 수정일: 2026년 1월 29일 | 채택일: 2026년 2월 6일