https://doi.org/10.14368/jdras.2026.42.3.200
ISSN 2384-4353 eISSN 2384-4272

Original Article

CBCT analysis of factors affecting maxillary sinus pneumatization following posterior tooth extraction: a retrospective study

Soo-yeon Shin, Seong-Nyum Jeong, Yeon-Tae Kim*
Department of Periodontics, College of Dentistry, Wonkwang University, Iksan, Republic of Korea

Purpose: This study aimed to quantify sinus pneumatization following maxillary posterior tooth extraction using cone-beam computed tomography (CBCT) and to identify associated factors. **Materials and Methods:** CBCT data obtained before extraction (T0) and at least 3 months after extraction (T1) were collected. At T0, root type (RT), sinus contour type (SCT), residual alveolar bone height (RBH), the time interval from extraction to T1, the position and number of extracted teeth, and the presence or absence of alveolar ridge preservation (ARP) were recorded. Sinus pneumatization height (SPH) was measured at both T0 and T1, and the difference between the two time points (ΔSPH) was calculated. The associations between the recorded factors and ΔSPH were analyzed. **Results:** A total of 50 patients and 63 sites were included. The overall mean ΔSPH was 0.29 ± 0.52 mm. Among these, the 50 sites where only extraction was performed showed a mean ΔSPH of 0.44 ± 0.42 mm. In contrast, the 13 sites that underwent ARP showed a mean ΔSPH of -0.06 ± 0.16 mm, which was significantly lower than that of the extraction-only sites. Sites with RBH < 10 mm demonstrated significantly greater pneumatization than those with RBH ≥ 10 mm, and a negative correlation was observed between RBH and ΔSPH. Furthermore, second molar extraction sites showed significantly greater pneumatization than first molar sites. **Conclusion:** Greater maxillary sinus pneumatization was observed in cases involving second molar extraction, lower pre-extraction RBH, and extraction performed without ARP. **(J Dent Rehabil Appl Sci 2026;42(3):200-12)**

Key words: tooth extraction; maxillary sinus; pneumatization; cone-beam computed tomography

Introduction

After tooth extraction, the alveolar bone undergoes a physiological remodeling process characterized by both vertical and horizontal changes.[1] Excessive bone resorption may limit implant placement and often require supplementary bone grafting procedures, which can increase treatment complexity and surgical invasiveness.[2]

This challenge is particularly pronounced in the posterior maxilla, where the close anatomical relationship between tooth roots and the maxillary sinus floor restricts available bone height for implant placement.[3] Consequently, sinus floor elevation is frequently performed to obtain sufficient bone volume.[4]

Progressive downward expansion of the maxillary sinus - known as sinus pneumatization - is a well-documented consequence of tooth extraction.[5] Sharan and Madjar[6] and Ulm et al.[7] have demonstrated that, over time, the sinus floor migrates inferiorly toward the alveolar crest, further diminishing bone height available for implants.

Classification of relationship between the roots of the maxillary molars and the maxillary sinus floor

*Correspondence to: Yeon-Tae Kim
Professor, Department of Periodontics, Daejeon Dental Hospital, Wonkwang University, 77 Doonsan-ro, Seo-gu, Daejeon, 35233, Republic of Korea
Tel: +82-42-366-1149, Fax: +82-42-366-1115, E-mail: ytkim0103@naver.com
Received: May 26, 2026/Last Revision: June 22, 2026/Accepted: June 23, 2026

Copyright© 2026 The Korean Academy of Stomatognathic Function and Occlusion.
©It is identical to Creative Commons Non-Commercial License.

(MSF) is proposed by Sharan and Madjar[8] and Pei et al.[9] Also, new classification of maxillary sinus contours derived from a combination of angle A (angle between the buccal and palatal alveolar wall), PNR (palate-nasal recess), sinus depth, and sinus width proposed by Niu et al.[10]

Previous studies have demonstrated that sinus pneumatization is influenced by factors such as maxillary sinus morphology, the sinus-root relationship, the duration after extraction, the tooth site (second premolar, first molar, or second molar), the number of extracted teeth, and the presence of alveolar ridge preservation (ARP).[5,6,11] Sharan and Madjar reported that sinus pneumatization was greater following the extraction of teeth enveloped by a superiorly curving sinus floor, extraction of multiple adjacent posterior teeth, and the extraction of second molars.[6] Lim et al. also reported that "the extraction of a second molar led to the greatest extent of pneumatization".[5] However, these previous studies have primarily relied on panoramic radiographs to assess sinus pneumatization. Two-dimensional imaging provides limited diagnostic accuracy because of anatomic overlaps and unclear sinus boundaries. Thus, high-resolution three-dimensional assessment tools are required.

Cone-beam computed tomography (CBCT) offers superior spatial resolution for evaluating maxillofacial structures and allow accurate volumetric measurement of sinus changes. CBCT analysis proposed by Wang et al. showed that the extent of pneumatization was mainly affected by extraction and site, rather than by its cause, such as periodontitis, periapical lesion, or tooth fracture.[12] Therefore, this study aimed to quantitatively evaluate post-extraction maxillary sinus pneumatization by comparing pre- and post-extraction CBCT scans to identify factors influencing its extent.

Materials and Methods

Ethical Statements

This retrospective radiographic study was approved with an exemption from the Institutional Review Board of Wonkwang University (IRB No. 202508-084-01). This was followed by the Strengthening the Reporting of Observational Studies in Epidemiology (STROBE) guidelines.[13]

Participants

50 patients who underwent extraction of maxillary posterior teeth at the Department of Periodontology, Daejeon Dental Hospital, Wonkwang University, between October 2012 and July 2025, were screened.

The inclusion criteria were as follows: (1) minimum age of 18 years, (2) healthy or well-controlled systemic diseases, (3) CBCT scans taken before tooth extraction and at least 3 months after extraction, and (4) the presence of a visible sinus floor on the coronal CBCT view.

The exclusion criteria were as follows: (1) uncontrolled systemic disease (e.g., diabetes, hypertension), (2) missing pre- or post-extraction CBCT images, (3) poor image quality hindering evaluation, (4) large periapical lesions altering sinus morphology, (5) root apex protruding into the sinus cavity.

Ultimately, 50 patients (63 extraction sites) were included. The flowchart of this study is presented in Fig. 1.

Data Collection

Through computerized clinical records, we collected data including sex, age, the time interval between extraction and T1 (≤ 6 months, > 6 months and ≤ 12 months, or > 12 months), tooth site, number of extracted teeth, and the presence of ARP at the time of extraction.

The surgical procedure of ARP was obtained from existing clinical records. ARP was performed immediately after tooth extraction using a deproteinized porcine bone mineral with 10% collagen (Legograft®; Purgo, Seongnam, Korea), which was placed into the extraction socket. Then, a collagen membrane, Remaix™ (Matricel GmbH, Herzogenrath, Germany) or Ossix Plus® (Datum Dental Biotech, Telrad, Israel) was applied to cover the grafted site.

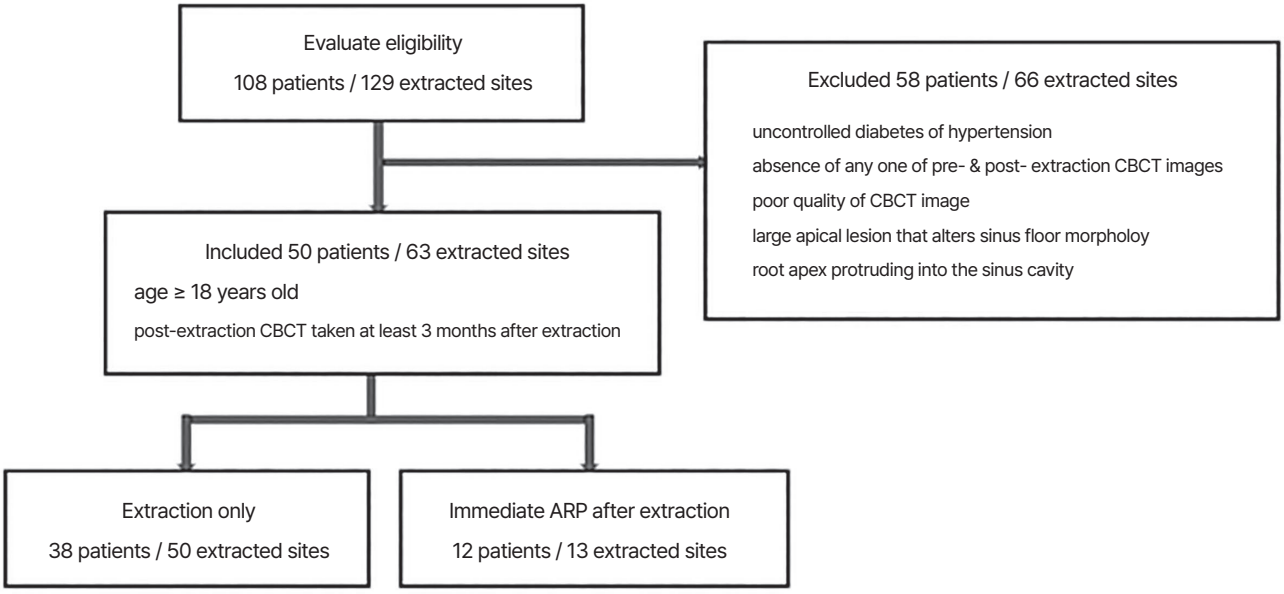

Fig. 1. Flowchart of patients recruitment and study design.
CBCT: Cone-beam computed tomography; ARP: alveolar ridge preservation.

Radiographic measurement

CBCT images (CS 8100 3D®, Carestream, Rochester, New York, USA) obtained before tooth extraction (T0) and at least 3 months after extraction (T1) were analyzed. T0 was defined as the most recent CBCT scan available before tooth extraction. Because of the retrospective nature of this study, the interval between T0 image acquisition and tooth extraction varied among patients. All CBCT scans were acquired using I-mode with an 80 × 90 mm field of view (FOV), a voxel size of 0.15 mm, and 90 kV. DICOM data were reconstructed using OnDemand3D® software (Cybermed, Seoul, Korea), and coronal sections of the CBCT scans were analyzed. Slice selection was standardized by anatomical landmark alignment, ensuring that the anterior nasal spine (ANS) was depicted in a consistent location at both time points (T0 and T1).

Two calibrated examiners independently performed all measurements using INFINITT® software (Infinitt Healthcare, Seoul, Korea). Intra- and inter- examiner reliability were tested on 10 randomly selected pairs; intra-class correlation coefficients (ICCs) > 0.95 confirmed excellent reproducibility. Measurement precision was 0.01 mm.

The following various parameters were measured by CBCT images:

- Root types (RT): On the pre-extraction CBCT images, the following relationship between the root and the sinus floor was classified: i) Root type 1: The maxillary sinus floor (MSF) is located above the root apex, ii) Root type 2: The root apex touches the maxillary sinus floor, iii) Root type 3: The maxillary sinus floor is interposed between the roots (Fig. 2).
- Sinus contour types (SCT): The sinuses are classified into the following types based on their configuration, which includes the sinus floor, buccal and palatal walls; Type A: narrow tapered; Type B: tapering; Type C: ovoid; Type D: square; Type E: irregular (Fig. 3).
- Residual alveolar bone height (RBH): The distance between the alveolar crest and the maxillary sinus floor was measured at the midpoint between the buccal cortical bone plate (BP) and palatal cortical bone plate (PP).[14] RBH was classified as < 10 mm and ≥ 10 mm (Fig. 4).
- Sinus pneumatization height (SPH): The vertical distance (mm) from the lowest point of the maxillary sinus floor (MSF) to the nasal cavity floor (NCF) was measured both before and after

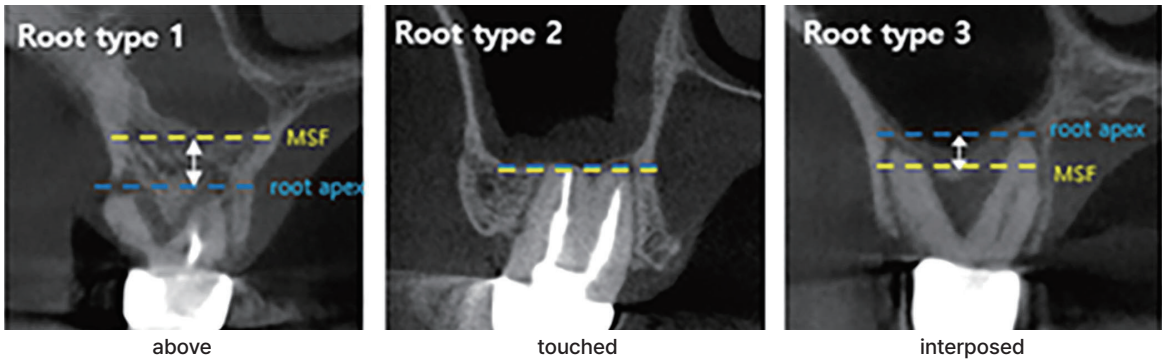

Fig. 2. The vertical relationship between the maxillary sinus floor and the maxillary molar roots. Root type 1: MSF located above the root apex; Root type 2: root apex touches the MSF; Root type 3: MSF is interposed between the roots; MSF: maxillary sinus floor.

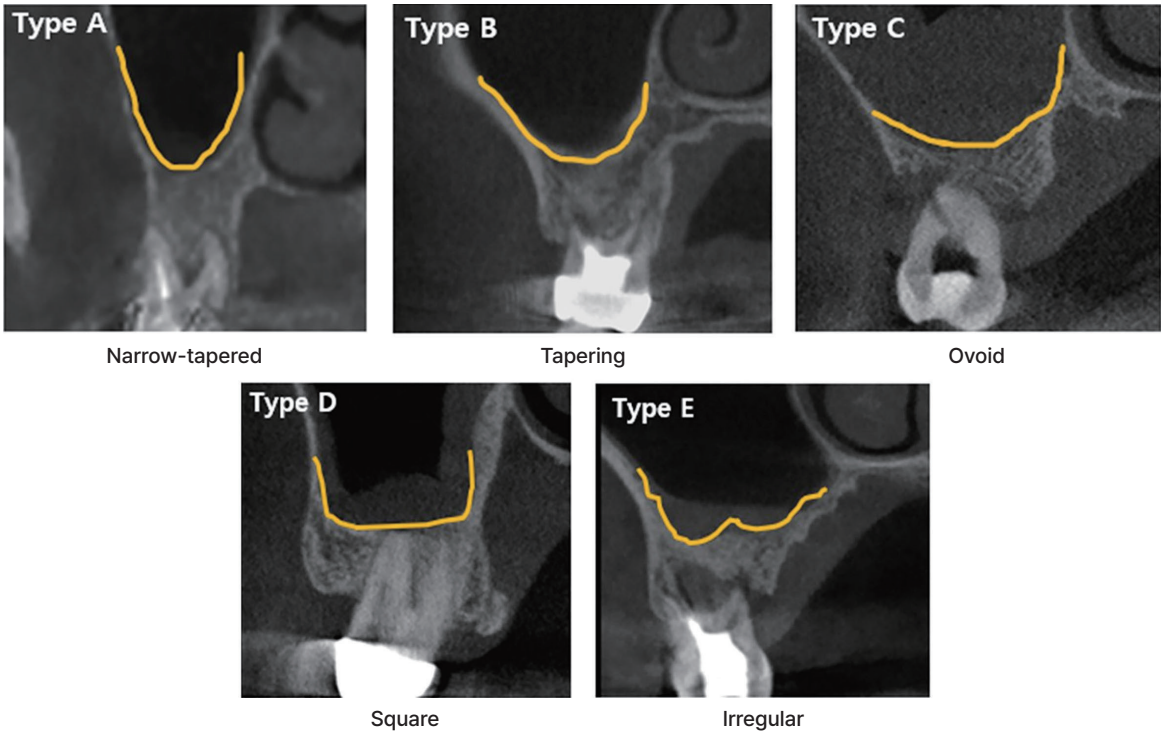

Fig. 3. Five types of maxillary sinus contour on coronal images. Type A: narrow tapered; Type B: tapering; Type C: ovoid; Type D: square; Type E: irregular.

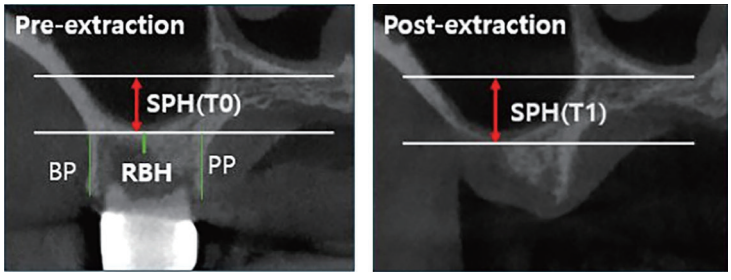

Fig. 4. Residual bone height (RBH) measured on pre-extraction CBCT. RBH was measured at the midpoint (center) between the BP and PP. BP: buccal cortical bone plate; PP: palatal cortical bone plate. Sinus pneumatization height (SPH) was measured on pre- (T0) & post-extraction (T1) CBCT. SPH was defined as the vertical distance (mm) from the lowest point of the maxillary sinus floor (MSF) to the nasal cavity floor (NCF).

extraction, and the change in this value was calculated. A negative value of SPH was recorded if the NCF was located below the MSF.[15] The change value was denoted as ΔSPH, which was calculated as SPH(T1) - SPH(T0) (Fig. 4).

Statistical analysis

Statistical analyses were performed with SPSS software (Version 29.0; SPSS Inc., Chicago, USA). The mean value and standard deviations of the ΔSPH were calculated. The associations of statistically significant factors (root type, contour type, residual bone height, time interval extraction - T1, tooth site, single/multiple extraction, presence of ARP) with the outcome parameters (ΔSPH) were analyzed using Kruskal-Wallis test or Mann-Whitney test, as appropriate. Correlations between RBH and ΔSPH were evaluated by Spearman's correlations test. A *P*-value of < 0.05 was considered statistically significant.

Results

A total of 50 patients (30 males and 20 females), ranging from 39 to 79 years (mean age 55.79 ± 9.32) were included in this study. Among the 63 extracted sites, 50 sites underwent extraction alone, while 13 sites received alveolar ridge preservation.

Based on the distribution of factors in Table 1, in all teeth, Root type 1 was the most common morphology (60.3%), followed by Root type 3 (25.4%) and Root type 2 (14.3%). Regarding the sinus con-

Table 1. The distribution of overall factors

Group	Extraction-only	ARP	All teeth
Root type			
Root type 1	31 (62.0%)	7 (53.8%)	38 (60.3%)
Root type 2	7 (14.0%)	2 (15.4%)	9 (14.3%)
Root type 3	12 (24.0%)	4 (30.8%)	16 (25.4%)
Sinus contour type			
Type A	13 (26.0%)	2 (15.4%)	15 (23.8%)
Type B	14 (28.0%)	4 (30.8%)	18 (28.6%)
Type C	2 (4.0%)	0 (0.0%)	2 (3.2%)
Type D	5 (10.0%)	2 (15.4%)	7 (11.1%)
Type E	16 (32.0%)	5 (38.5%)	21 (33.3%)
Residual bone height			
< 10 mm	41 (82.0%)	13 (100.0%)	54 (85.7%)
≥ 10 mm	9 (18.0%)	0 (0.0%)	9 (14.3%)
Ext.~post CT (T1) interval			
≤ 6 months	34 (68.0%)	12 (92.3%)	46 (73.0%)
> 6 and ≤ 12 months	10 (20.0%)	1 (7.7%)	11 (17.5%)
> 12 months	6 (12.0%)	0 (0.0%)	6 (9.5%)
Tooth site			
Second premolar	2 (4.0%)	1 (7.7%)	3 (4.8%)
First molar	29 (58.0%)	9 (69.2%)	38 (60.3%)
Second molar	19 (38.0%)	3 (23.1%)	22 (34.9%)
Number of extracted teeth			
Single extraction	40 (80.0%)	11 (84.6%)	51 (81.0%)
Multiple extraction	10 (20.0%)	2 (15.4%)	12 (19.0%)

Extraction-only: extraction alone; ARP: alveolar ridge preservation; Root type 1: above; Root type 2: touched; Root type 3: interposed; Type A: narrow tapered; Type B: tapering; Type C: ovoid; Type D: square; Type E: irregular; T1: time point CBCT was taken after extraction; n (%).

tour classification, Type E (33.3%), Type B (28.6%), and Type A (23.8%) were the most frequently observed. Residual bone height (RBH) before extraction was < 10 mm in most sites (85.7%), whereas only a smaller proportion (14.3%) exhibited an RBH ≥ 10 mm. The time interval between extraction and T1 was ≤ 6 months in 73.0%, > 6 to ≤ 12 months in 17.5%, and > 12 months in 9.5%. Regarding tooth site, first molars accounted for the largest proportion (60.3%, 38 sites), followed by second molars (34.9%, 22 sites) and second premolars (4.8%, 3 sites). In terms of the number of extracted teeth, single-extraction cases comprised 81.0%, whereas multiple-extraction cases accounted for 19.0%.

Regarding root type, the mean ΔSPH was 0.41 ± 0.08 mm for Root type 1 (above), 0.39 ± 0.15 mm for Type 2 (touched), and 0.54 ± 0.11 mm for Type 3 (interposed) (Table 2). Although the interposed group exhibited the greatest increase in ΔSPH, differences among the three root types did not reach statistical significance (P = 0.398).

Regarding sinus contour type, the mean ΔSPH was 0.61 ± 0.17 mm for Type A (narrow-tapered), 0.39 ± 0.86 mm for Type B (tapering), 0.43 ± 0.19 mm for Type C (ovoid), 0.32 ± 0.14 mm for Type D (square), and 0.39 ± 0.81 mm for Type E (irregular) (Table 2). Although Type A exhibited the greatest increase in Δ SPH, no statistically significant difference was found among the five contour types (P = 0.892).

Regarding residual bone height (RBH), site with < 10 mm of RBH demonstrated a significantly greater increase in ΔSPH (0.46 ± 0.06 mm) compared with those with ≥ 10 mm (0.30 ± 0.06 mm, P = 0.021) (Table 2) (Fig. 5). A significant negative correlation was observed between RBH and ΔSPH in the extraction-only group (r = -0.293, P = 0.039) (Table 3).

Regarding tooth site, ΔSPH was 0.13 ± 0.05 mm at second premolar sites, 0.37 ± 0.72 mm at first molar sites, and 0.57 ± 0.10 mm at second molar sites (Table 2). A significantly greater pneumatization was observed at second molar sites compared with other regions (P = 0.038) (Fig. 6).

Regarding the time interval between extraction and T1, ΔSPH was 0.39 ± 0.06 mm at ≤ 6 months, 0.40 ± 0.11 mm at > 6 to ≤ 12 months, and 0.69 ± 0.28

Table 2. Comparison of ΔSPH according to factors

Group	ΔSPH (mm)	
	Extraction-only	ARP
Root type		
Root type 1	0.41 ± 0.08	0.22 ± 0.11
Root type 2	0.39 ± 0.15	-0.78 ± 0.76
Root type 3	0.54 ± 0.11	-0.18 ± 0.20
P	0.398	0.100
Sinus contour type		
Type A	0.61 ± 0.17	-0.31 ± 0.31
Type B	0.39 ± 0.86	-0.21 ± 0.51
Type C	0.43 ± 0.19	-
Type D	0.32 ± 0.14	0.07 ± 0.07
Type E	0.39 ± 0.81	0.11 ± 0.05
P	0.892	0.530
Residual bone height		
< 10 mm	0.46 ± 0.06*	-0.06 ± 0.16
≥ 10 mm	0.30 ± 0.23*	-
P	0.021*	-
Time interval following extraction		
≤ 6 months	0.39 ± 0.06	-0.15 ± 0.16
> 6 and ≤ 12 months	0.40 ± 0.11	0.42 ± 0.42
> 12 months	0.69 ± 0.28	-
P	0.540	0.513
Tooth site		
Second premolar	0.13 ± 0.05	0.13
First molar	0.37 ± 0.72*	0.01 ± 0.21
Second molar	0.57 ± 0.10*	-0.33 ± 0.18
P	0.038*	0.161
Number of extracted teeth		
Single extraction	0.43 ± 0.07	-0.02 ± 0.18
Multiple extraction	0.48 ± 0.09	-0.25 ± 0.37
P	0.270	0.513

Data are shown as mean ± standard deviation or n (%); An asterisk is used to identify comparisons demonstrating statistical significance between groups (P < 0.05).
SPH: sinus pneumatization height; ΔSPH: SPH (T1) - SPH (T0); T0: time point CBCT was taken before extraction; T1: time point CBCT was taken after extraction.

Table 3. Spearman's correlation test between residual bone height and sinus pneumatization height in extraction-only sites

Correlation anaylsis		
	ΔSPH (mm) in extraction-only	
RBH	r	-0.293
	P	0.039*

*P < 0.05.
RBH: residual bone height; SPH: sinus pneumatization height.

mm at > 12 months, showing no statistically significant difference among the groups (P = 0.54) (Table 2).

Regarding the number of extracted teeth, ΔSPH was higher in multiple extraction sites. However, there was no significant difference between single extraction sites (0.43 ± 0.07 mm) and multiple extraction sites (0.48 ± 0.09 mm, P = 0.27) (Table 2).

When comparing sites that underwent extraction only and those treated with ARP, a significant difference in ΔSPH was observed (Table 3). The mean ΔSPH was 0.44 ± 0.24 mm in the extraction-only group and -0.06 ± 0.16 mm in the extraction with ARP group, indicating significantly less pneumatization in sites where ARP was performed (P = 0.001) (Fig. 7).

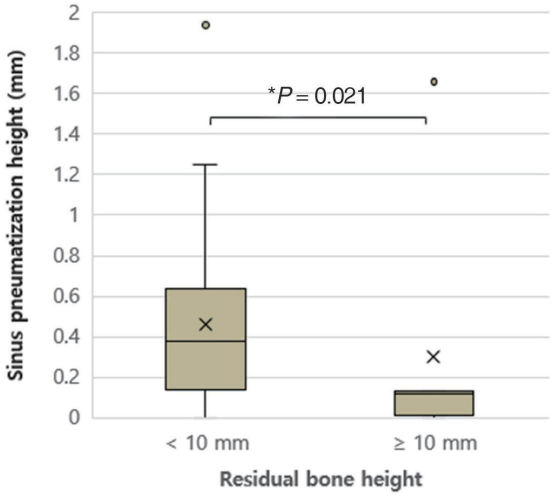

Fig. 5. Sinus pneumatization height according to residual bone height. The asterisks indicate statistically significant differences between groups (P < 0.05).

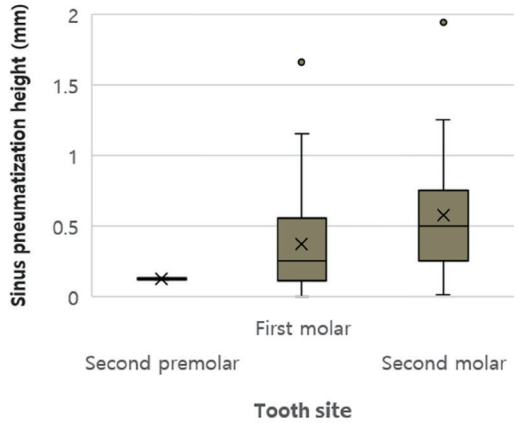

Fig. 6. Sinus pneumatization height according to tooth site.

Discussion

This retrospective CBCT-based study quantitatively evaluated maxillary sinus pneumatization following posterior maxillary tooth extraction. The average extent of sinus pneumatization was 0.29 ± 0.52 mm across 63 total sites, with significant differences observed between extraction-only sites (0.44 ± 0.42 mm) and alveolar ridge preservation (ARP) sites (-0.06 ± 0.16 mm). These findings offer valuable insights into the anatomical changes that occur in the posterior maxilla after tooth loss and have important implications for treatment planning in implant dentistry.[16,17]

In this study, root type 3 (interposed) exhibited the highest mean value of Δ SPH (0.54 ± 0.11 mm), followed by root type 1 (above, 0.41 ± 0.08 mm) and root type 2 (touched, 0.39 ± 0.15 mm). However, this difference was not statistically significant (P = 0.398). This finding aligns with previous studies, which reported that the vertical positional relationship between the sinus floor and the root apex is not consistently associated with the extent of pneumatization.[5,6]

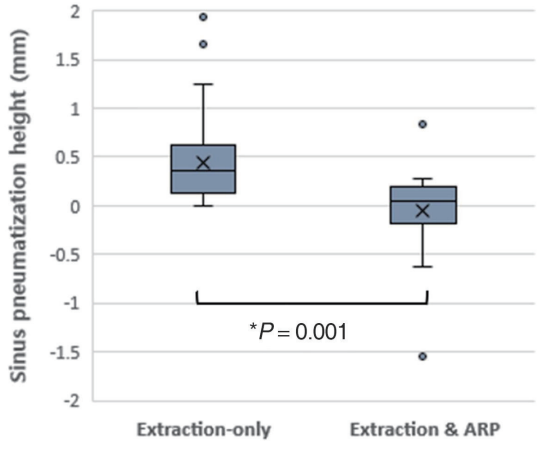

Fig. 7. Sinus pneumatization height according to extraction-only vs. alveolar ridge preservation. The asterisks indicate statistically significant differences between groups (P < 0.05).

The relationship between root apex position and sinus pneumatization remains controversial. Sharan et al. reported that teeth with roots surrounded by an upwardly curved sinus floor demonstrated the greatest pneumatization.[6] However, Jung et al. found no significant impact of root-sinus relationship on pneumatization extent, and Lim et al. reported contradictory findings, with different root classifications showing the greatest pneumatization depending on residual bone height.[5,18] These discrepancies may be attributed to methodological factors, including the difficulty in establishing precise sinus floor positions on different imaging modalities and variations in root anatomy.

Our results suggest that the root-sinus positional relationship may not serve as a reliable predictor of the extent of sinus pneumatization. Although root type 3 showed numerically higher values, the lack of statistical significance suggests that sinus pneumatization may result from the combined influence of other factors – such as the number of extracted teeth, endodontic status, sinus membrane thickness, etc.[5]

The analysis of sinus contour types revealed that Type A (narrow-tapered) exhibited the greatest increase in sinus pneumatization height (0.61 ± 0.17 mm), while Type D (square) showed the smallest change (0.32 ± 0.14 mm). Despite these numerical differences, no statistically significant differences were found among the five contour types ($P = 0.892$).

Type A, characterized by its narrow, tapered configuration, is expected to have limited potential for lateral expansion, thereby directing pneumatization preferentially in the vertical dimension.[19,20] The lack of statistical significance may be attributed to the relatively small sample sizes within each contour type subgroup and the uneven distribution across types. Additionally, the two-dimensional classification system used in this study may not fully capture the three-dimensional complexity of sinus anatomy. Future studies employing three-dimensional volumetric analysis of sinus shape could provide more detailed insights into this relationship.

Regarding tooth sites, the finding that second molar sites exhibit significantly greater pneumatization (0.57 ± 0.10 mm) compared to first molar sites (0.37 ± 0.72 mm) and second premolar sites (0.13 ± 0.05 mm) is consistent with previous studies by Lim et al.[5] and Sharan and Madjar.[6] This regional variation can be attributed to several anatomical factors. First, the second molar region is characterized by poor bone quality, with a higher proportion of trabecular bone and thinner cortical plates compared to more anterior regions.[21,22] Second, the second molar area typically exhibits closer proximity between the root apex and the sinus floor, resulting in a thinner alveolar bone that is more readily remodeled after extraction.[23] Third, first molars, being larger teeth with a greater root surface area, may leave behind more substantial alveolar housing after extraction, potentially limiting the space available for sinus expansion.[24,25]

One of the most clinically significant findings was the strong negative correlation between residual bone height (RBH) and sinus pneumatization. Sites with an RBH < 10 mm exhibited significantly greater pneumatization (0.46 ± 0.06 mm) compared to those with an RBH ≥ 10 mm (0.30 ± 0.06 mm, $P = 0.021$). This correlation ($r = -0.293$, $P = 0.039$) suggests that patients with initially limited bone height are at a higher risk of further bone loss due to pneumatization.

Areas with reduced RBH often indicate that the sinus floor was already close to the alveolar crest before tooth extraction.[26] Following extraction, the loss of mechanical stimulation and subsequent remodeling tend to occur more prominently in regions where bone mass is already diminished.[6,27,28] Thinner bone partitions between the extraction socket and the sinus floor are more likely to undergo remodeling during healing, facilitating downward migration of the sinus mucosa.[5,29]

The clinical implications are significant. Patients presenting with RBH < 10 mm prior to extraction should be considered at higher risk for developing insufficient bone height for implant placement. In such cases, clinicians should consider implementing preventive strategies, such as performing alveolar ridge preservation concurrently with tooth extraction.[30] The association between reduced RBH and increased ΔSPH may also partially explain the regional

differences observed in this study, as second molar areas typically exhibit lower mean RBH values, possibly due to root convergence or fusion commonly observed in second molars.[31]

Contrary to previous reports by Sharan et al. and Jung et al., which demonstrated greater sinus pneumatization following multiple extractions, this study found no statistically significant difference (0.43 ± 0.07 mm for single extraction versus 0.48 ± 0.09 mm for multiple extractions; $P = 0.270$).[6,18]

This discrepancy may be attributed to the relatively small sample size in the multiple extraction group (n = 12, 19.0%) compared to the single extraction group (n = 51, 81.0%), which may have limited the statistical power. Additionally, the spatial distribution and timing of multiple extractions (simultaneous versus sequential) were not systematically analyzed, which could have influenced the outcomes. The specific combinations of teeth extracted may also have distinct impacts on pneumatization patterns due to differences in root morphology and bone volume at various sites.[6]

The most clinically significant finding of this study was the substantial difference in pneumatization between extraction-only sites and ARP sites. Sites where ARP was performed demonstrated minimal or negative mean pneumatization (-0.06 ± 0.16 mm) compared to extraction-only sites (0.44 ± 0.42 mm, $P = 0.001$), representing a reduction of approximately 0.5 mm in sinus floor migration.

The mechanisms by which alveolar ridge preservation (ARP) mitigates sinus pneumatization are multifactorial. First, placing bone graft material helps maintain the alveolar ridge volume by providing structural support to prevent sinus expansion.[32] Second, the graft material serves as a scaffold for new bone formation, creating a more robust barrier between the sinus cavity and the alveolar crest.[33] Third, ARP procedures typically involve coverage with a barrier membrane, which helps stabilize the graft and create a protected environment for bone healing.[34]

These findings are consistent with previous studies by Cha et al. and Lombardi et al., reinforcing the evidence supporting ARP as a standard procedure when implant rehabilitation is planned, especially in the posterior maxilla, where the risk of pneumatization is greatest.[11,33] ARP not only prevents pneumatization but also maintains the three-dimensional position of the alveolar crest, which is essential for ideal implant placement.

The analysis of pneumatization relative to the interval between extraction and post-extraction CBCT showed a trend toward increased pneumatization with longer follow-up periods; however, this trend did not reach statistical significance ($P = 0.54$). Mean ΔSPH values were 0.39 ± 0.06 mm at ≤ 6 months, 0.40 ± 0.11 mm at 6 - 12 months, and 0.69 ± 0.28 mm beyond 12 months.

The lack of statistical significance may be attributed to the retrospective design which resulted in variable intervals and an uneven distribution of cases across time categories. Nevertheless, the numerical trend suggests that pneumatization may persist beyond the initial healing period. Previous longitudinal studies have demonstrated that maxillary sinus pneumatization may continue for several years after tooth extraction, although the rate of change gradually declines over time.[35,36] This finding has important implications for the timing of implant placement, as delaying treatment for extended periods may lead to progressive loss of bone height.[37]

There are some limitations in this study. First, due to the retrospective nature of this study, the time intervals from T0 to extraction and from extraction to T1 varied significantly among patients, potentially allowing other factors to affect pneumatization during this period. Second, CBCT scans are frequently obtained 3 to 4 months after extraction for implant placement. This duration may not be sufficient for assessing pneumatization. Third, the use of single-point measurements on CBCT images limits the ability to fully characterize the complex 3-dimensional relationship between the maxillary sinus floor and the roots. This methodological limitation underscores the need for future research utilizing comprehensive volumetric analyses to more accurately assess spatial changes and anatomical variations over time. Fourth, the mean ΔSPH observed in the ARP group (-0.06 ± 0.16 mm) was smaller than the voxel size of the CBCT images (0.15 mm). Therefore, this value

should be interpreted cautiously because it may fall within the range of measurement uncertainty. Although excellent intra- and inter-examiner reliability was confirmed, the possibility of measurement error cannot be completely excluded. Fifth, the potential selection bias associated with ARP treatment. Because treatment decisions were made based on clinical judgment in this retrospective study, the baseline characteristics were not evenly distributed between the ARP and non-ARP groups. Cases with sufficient residual bone height were underrepresented in the ARP group, which may have influenced the observed association between ARP and sinus pneumatization. Finally, the sample size was relatively limited due to the challenging task of acquiring suitable CBCT datasets that met all inclusion criteria. Further clinical trials should adopt a prospective study design with larger cohorts.

Conclusion

1. CBCT analysis demonstrated that maxillary sinus pneumatization was greater when second molars were extracted.
2. Sites with a lower residual bone height before extraction showed greater degree of sinus pneumatization.
3. Sites that underwent extraction alone exhibited greater sinus pneumatization compared to sites with alveolar ridge preservation.
4. These findings are important for planning implant placement in ideal positions following maxillary molar extraction.

ORCID

Soo-yeon Shin https://orcid.org/0009-0000-5168-755X
Seong-Nyum Jeong https://orcid.org/0000-0003-4890-989X
Yeon-Tae Kim https://orcid.org/0000-0001-7209-3208

References

1. Van der Weijden F, Dell'Acqua F, Slot DE. Alveolar bone dimensional changes of post-extraction sockets in humans: a systematic review. J Clin Periodontol 2009;36:1048-58.
2. Milinkovic I, Cordaro L. Are there specific indications for the different alveolar bone augmentation procedures for implant placement? A systematic review. Int J Oral Maxillofac Surg 2014;43:606-25.
3. Lundgren S, Cricchio G, Hallman M, Jungner M, Rasmusson L, Sennerby L. Sinus floor elevation procedures to enable implant placement and integration: techniques, biological aspects and clinical outcomes. Periodontol 2000 2017;73:103-20.
4. Esposito M, Grusovin MG, Rees J, Karasoulos D, Felice P, Alissa R, Worthington H, Coulthard P. Effectiveness of sinus lift procedures for dental implant rehabilitation: a Cochrane systematic. Eur J Oral Implantol 2010;3:7-26.
5. Lim HC, Kim S, Kim DH, Herr Y, Chung JH, Shin SI. Factors affecting maxillary sinus pneumatization following posterior maxillary tooth extraction. J Periodontal Implant Sci 2021;51:285-95.
6. Sharan A, Madjar D. Maxillary sinus pneumatization following extractions: a radiographic study. Int J Oral Maxillofac Implants 2008;23:48-56.
7. Ulm CW, Solar P, Gselimann B, Matejka M, Watzek G. The edentulous maxillary alveolar process in the region of the maxillary sinus-a study of physical dimension. Int J Oral Maxillofac Surg 1995;24:279-82.
8. Sharan A, Madjar D. Correlation between maxillary sinus floor topography and related root position of posterior teeth using panoramic and cross-sectional computed tomography imaging. Oral Surg Oral Med Oral Pathol Oral Radiol Endod 2006;102:375-81.
9. Pei J, Liu J, Chen Y, Liu Y, Liao X, Pan J. Relationship between maxillary posterior molar roots and the maxillary sinus floor: cone-beam computed tomography analysis of a western Chinese population. J Int Med Res 2020;48:0300060520926896.
10. Niu L, Wang J, Yu H, Qiu L. New classification of maxillary sinus contours and its relation to sinus floor elevation surgery. Clin Implant Dent Relat Res 2018;20:493-500.
11. Cha JK, Sonh YW, Park SH, Jung RE, Jung UW, Thoma DS. Alveolar ridge preservation in the posterior maxilla reduces vertical dimensional change:

A randomized controlled clinical trial. Clin Oral Implants Res 2019;30:515-23.
12. Wang M, Mao FF, Jin XH, Huang JP, Dai A, Ding PH. The influence of different extraction indications on the morphological changes in the maxillary sinus: A retrospective cohort study. J Periodontal Res 2025;60:570-80.
13. Von Elm E, Altman DG, Egger M, Pocock SJ, Gøtzsche PC, Vandenbroucke JP. The Strengthening the Reporting of Observational Studies in Epidemiology (STROBE) statement: guidelines for reporting observational studies. Lancet 2007;370: 1453-7.
14. Wei Y, Xu T, Zhao L, Hu W, Chung KH. Ridge preservation in maxillary molar extraction sites with severe periodontitis: a prospective observational clinical trial. Clin Oral Investig 2022;26:2391-9.
15. Wagner F, Dvorak G, Nemec S, Pietschmann P, Traxler H, Schicho K, Seemann R. Morphometric analysis of sinus depth in the posterior maxilla and proposal of a novel classification. Sci Rep 2017;7: 45397.
16. King ME, Schofield J. Restoratively driven planning for implants in the posterior maxilla-Part 1: alveolar bone healing, bone assessment and clinical classifications. Br Dent J 2023;235:585-92.
17. Lee JE, Jin SH, Ko Y, Park JB. Evaluation of anatomical considerations in the posterior maxillae for sinus augmentation. World J Clin Cases 2014;2:683-8.
18. Jung YH, Nah KS, Cho BH. Maxillary sinus pneumatization after maxillary molar extraction assessed with cone beam computed tomography. Korean J Oral Maxillofac Radiol 2009;39:109-13.
19. Smith TD, Rossie JB, Bhatnagar KP. Evolution of the nose and nasal skeleton in primates. Evol Anthropol 2007;16:132-46.
20. Maddux SD, Butaric LN. Zygomaticomaxillary morphology and maxillary sinus form and function: how spatial constraints influence pneumatization patterns among modern humans. Anat Rec 2017; 300:209-25.
21. Chugh T, Ganeshkar SV, Revankar AV, Jain AK. Quantitative assessment of interradicular bone density in the maxilla and mandible: implications in clinical orthodontics. Prog Orthod 2013;14:38.
22. Krieger E, Wehrbein H. Interradicular trabecular bone density of the lateral maxilla for temporary anchorage devices-a histomorphometric study. Head Face Med 2015;11:1.
23. Zhang X, Li Y, Zhang Y, Hu F, Xu B, Shi X, Song L. Investigating the anatomical relationship between the maxillary molars and the sinus floor in a Chinese population using cone-beam computed tomography. BMC Oral Health 2019;19:282.
24. Gher MW Jr, Dunlap RW. Linear variation of the root surface area of the maxillary first molar. J Periodontol 1985;56:39-43.
25. Cai B, Zhao XG. Molar and incisor positioning to achieve occlusal and esthetic objectives. In: Nanda R, editor. Esthetics and Biomechanics in Orthodontics. St. Louis; Elsevier; 2014. p. 180-96.
26. Hameed S, Bakhshalian N, Alwazan E, Wallace SS, Zadeh HH. Maxillary sinus floor and alveolar crest alterations following extraction of single maxillary molars: a retrospective CBCT analysis. Int J Periodontics Restorative Dent 2019;39:545-51.
27. Hansson S, Halldin A. Alveolar ridge resorption after tooth extraction: a consequence of a fundamental principle of bone physiology. J Dent Biomech 2012;3:1758736012456543.
28. Pagni G, Pellegrini G, Giannobile WV, Rasperini G. Postextraction alveolar ridge preservation: biological basis and treatments. Int J Dent 2012;2012:151030.
29. Kim YK, Ku JK. Extraction socket preservation. J Korean Assoc Oral Maxillofac Surg 2020;46:435-9.
30. Lam L, Ivanovski S, Lee RS. Alveolar ridge preservation in posterior maxillary teeth for reduction in the potential need for sinus floor elevation procedures: a pilot study. Clin Oral Implants Res 2024; 35:1568-84.
31. Marcano-Caldera M, Mejia-Carnoda JL, del Pilar Blanco-Uribe M, Chaverra-Mesa EC, Rodriguez-Lezama D, Parra-Sanchez JH. Fused roots of maxillary molars: characterization and prevalence in a Latin American sub-population: a cone beam computed tomography study. Restor Dent Endod 2019; 44:e16.
32. Yu JE, Kim YT, Jeong SN. Alveolar ridge preservation of damaged maxillary molar extraction

sockets: a retrospective study. J Implantol Appl Sci 2025;29:69-79.

33. Lombard T, Bernardello F, Berton F, Porreli D, Rapani A, Camurri Piloni A, Fiorillo L, Di Lenarda R, Stacchi C. Efficacy of alveolar ridge preservation after maxillary molar extraction in reducing crestal bone resorption and sinus pneumatization: a multicenter prospective case-control study. Biomed Res Int 2018;2018:9352130.
34. Sano T, Kuraji R, Miyashita Y, Yano K, Kawanabe D, Numabe Y. Biomaterials for alveolar ridge preservation as a preoperative procedure for implant treatment: history and current evidence. Bioengineering 2023;10:1376.
35. Hatano N, Sennerby L, Lundgren S. Maxillary sinus augmentation using sinus membrane elevation and peripheral venous blood for implant-supported rehabilitation of the atrophic posterior maxilla: case series. Clin Implant Dent Relat Res 2007;9:150-5.
36. Wehrbein H, Diedrich P. Progressive pneumatization of the basal maxillary sinus after extraction and space closure. Fortschr Kieferorthop 1992;53:77-83.
37. Levi I, Halperin-Sternfeld M, Horwitz J, Zigdon-Giladi H, Machtei EE. Dimensional changes of the maxillary sinus following tooth extraction in the posterior maxilla with and without socket preservation. Clin Implant Dent Relat Res 2017;19:952-8.

상악 구치부 발치 후 상악동 함기화에 영향을 미치는 요인들에 대한 CBCT 분석: 후향적 연구

신수연 전공의, **정성념** 교수, **김연태*** 교수
원광대학교 치과대학 치주과학교실

목적: 콘빔 컴퓨터 단층 촬영(CBCT)을 기반으로 상악 구치부 발치 후 발생하는 상악동 함기화의 양을 정량화하고, 이에 영향을 미치는 요인들을 규명하고자 하였다.
연구 재료 및 방법: 발치 전(T0)과 발치 후 최소 3개월 후(T1)에 촬영된 CBCT 자료를 수집하였다. T0 시점에서 치근 형태(RT), 상악동 형태(SCT), 잔존 치조골 높이(RBH), 발치 후 T1까지의 간격, 발치한 치아 위치와 개수, 그리고 치조제 보존술(ARP) 유무를 기록하였다. T0 및 T1 시점에서 각각 상악동 함기화 높이(SPH)를 측정하였으며, 두 시점 간의 차이(ΔSPH)를 계산하였다. 기록된 요인들과 ΔSPH 사이의 연관성을 비교 분석하였다.
결과: 총 50명의 환자에서 63개의 부위가 포함되었다. 전체 ΔSPH 평균은 0.29 ± 0.52 mm였으며, 이 중 발치만 시행한 50개 부위에서는 평균 0.44 ± 0.42 mm이었다. 반면, ARP를 시행한 13개의 부위의 ΔSPH는 평균 -0.06 ± 0.16 mm로, 발치만 시행한 부위보다 유의하게 낮았다. 또한 RBH < 10 mm인 부위는 RBH ≥ 10 mm인 부위에 비해 유의하게 더 큰 함기화를 보였으며, RBH와 ΔSPH 사이에는 음의 상관관계가 나타났다. 제2대구치 발치 부위는 제1대구치보다 유의하게 더 큰 함기화를 보였다.
결론: 제2대구치를 발치한 경우, 발치 전 RBH가 낮은 경우, 그리고 ARP 없이 발치만 시행한 경우에서 유의하게 더 큰 함기화가 나타났다.

(구강회복응용과학지 2026;42(3):200-12)

주요어: 발치; 상악동; 함기화; 콘빔 컴퓨터 단층촬영

*교신저자: 김연태
(35233)대전광역시 서구 둔산로 77 원광대학교 치과대학 대전치과병원 치주과
Tel: 042-366-1149 | Fax: 042-366-1115 | E-mail: ytkim0103@naver.com
접수일: 2026년 5월 26일 | 수정일: 2026년 6월 22일 | 채택일: 2026년 6월 23일