https://doi.org/10.14368/jdras.2026.42.3.271
ISSN 2384-4353 eISSN 2384-4272

Case Report

Immediate-onset symptomatic irreversible pulpitis of an adjacent tooth following implant placement without radiographic root contact: a diagnostic challenge

Hee-Jin Kim*
Department of Dentistry, College of Medicine, Kosin University, Busan, Republic of Korea

This case describes an unusual early pulpal complication following immediate implant placement. A patient with a history of alcoholic hepatitis underwent implant placement at site #32 and experienced continuous discomfort from the day of surgery. Initial periodontal therapy failed, and referral revealed inconsistent pain reports at tooth #34. Comprehensive sensibility testing identified irreversible pulpitis in adjacent tooth #33, despite no radiographic evidence of pathology or implant-root contact. Root canal treatment resolved symptoms, and subsequent implant removal reduced mobility of #33, supporting mechanical or surgical trauma as the possible cause. This case emphasizes that implant-induced pulpal injury can occur without radiographic signs and may present with referred pain and misleading pain, especially in medically compromised patients with altered pain perception. The immediate onset of irreversible pulpitis distinguishes it from delayed complications previously reported, underscoring the importance of careful pulpal assessment of adjacent teeth when persistent symptoms arise after implant placement. **(J Dent Rehabil Appl Sci 2026;42(3):271-7)**

Key words: symptomatic irreversible pulpitis; implant-induced injury; alcoholic hepatitis; referred pain

Introduction

Dental implants have become a widely accepted treatment for tooth replacement due to their high success and survival rates. However, implants that have proximity to adjacent natural teeth carry a potential risk of pulpal or periapical complications.[1] While the overall prevalence of pulpal complications after implant placement is relatively low, clinicians should remain vigilant, as even subtle injuries can lead to irreversible pulpitis.

Most reported complications occur when the implant directly contacts the root or when a periapical lesion develops postoperatively, which are usually identifiable on radiographs.[2] Typical presentations include delayed-onset pulp necrosis, periapical radiolucency, or implant-root contact visible on imaging. In contrast, rare presentations, such as immediate-onset pulpal injury without radiographic evidence, are scarcely documented in the literature. Previous studies, including those by Lin et al.,[1] Yi et al.[2] have primarily described implant-induced pulpal injury as a delayed complication developing months to years after implant placement.

The present case highlights a unique clinical scenario in which irreversible pulpitis developed in a tooth adjacent to a newly placed implant within days of surgery, despite the absence of radiographic signs.

*Correspondence to: Hee-Jin Kim
Associate Professor, Department of Dentistry, College of Medicine, Kosin University, 262, Gamcheon-ro, Seo-gu, Busan, 49267, Republic of Korea
Tel: +82-51-990-6260, Fax: +82-51-990-3005, E-mail: island719@naver.com
Received: May 9, 2026/Last Revision: June 8, 2026/Accepted: June 8, 2026

Copyright© 2026 The Korean Academy of Stomatognathic Function and Occlusion.
©It is identical to Creative Commons Non-Commercial License.

Acute pulpitis is well known to produce referred pain, making it difficult for patients to accurately discriminate the true source of discomfort. This case demonstrates the diagnostic challenges associated with subtle implant-induced pulpal injury, particularly in medically compromised patients, and emphasizes the importance of careful clinical evaluation including pulp sensibility testing and percussion testing, rather than reliance on radiographs or patient's statements alone. Our aim is to raise awareness of this rare but clinically significant complication, which may be overlooked in typical post-implant assessments.

Case Report

A 71-year-old male patient with a medical history of hypertension, dyslipidemia, and chronic heavy alcohol consumption presented to our department in December 2025 for evaluation of persistent left mandibular pain. The patient had previously been hospitalized in September 2023 for acute alcoholic hepatitis with acute kidney injury and was under surveillance for possible chronic liver disease. The patient underwent immediate implant placement at the mandibular left lateral incisor region (#32) following extraction on September 13, 2025 at a private dental clinic (Fig. 1). From the day of surgery, the patient reported persistent discomfort localized to the left mandibular region. Despite initial management, including scaling and periodontal therapy, at the referring dental clinic, the symptoms persisted for two weeks. The patient was therefore referred to our department for further evaluation.

The implant fixture at site #32 was positioned in proximity but without direct radiographic contact to the root surface of the adjacent canine (#33) (Fig. 2A). No periapical radiolucency or signs of peri-implant pathology were observed. Tooth #34 presented with a curved root and a deep cervical restoration. Radiographic examination revealed an old porcelain-fused-to-metal crown on tooth #36 with previous root canal treatment and evidence of furcation involvement (Fig. 2B).

Clinically, tooth #33 exhibited a strong positive response to percussion, bite test, cold testing using a refrigerant spray (Endo Ice™, COLTENE/Whaledent Inc., Cuyahoga Falls, USA) with lingering pain, consistent with symptomatic irreversible pulpitis. Tooth #36 also demonstrated mild percussion sensitivity. Although the patient initially localized pain to tooth #34, which had a deep restoration, clinical testing showed normal air sensitivity, normal cold test response without lingering pain, and no percussion tenderness. Periodontal probing depths were within normal limits across all examined teeth. A selective diagnostic infiltration anesthetic test was then performed on tooth #33, after which the patient's previously reported pain radiating from the premolar to the molar region was reduced by approximately 60%, thereby supporting tooth #33 as the primary source of pain.

Root canal treatment was initiated on tooth #33

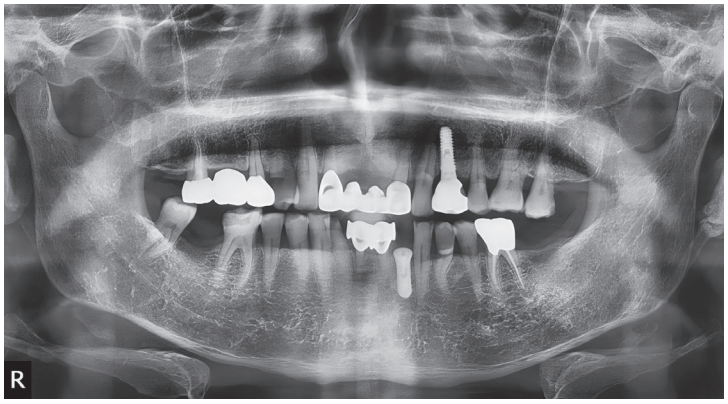

Fig. 1. Post-implant radiograph demonstrating implant #32 and the adjacent tooth root #33, with no evidence of contact.

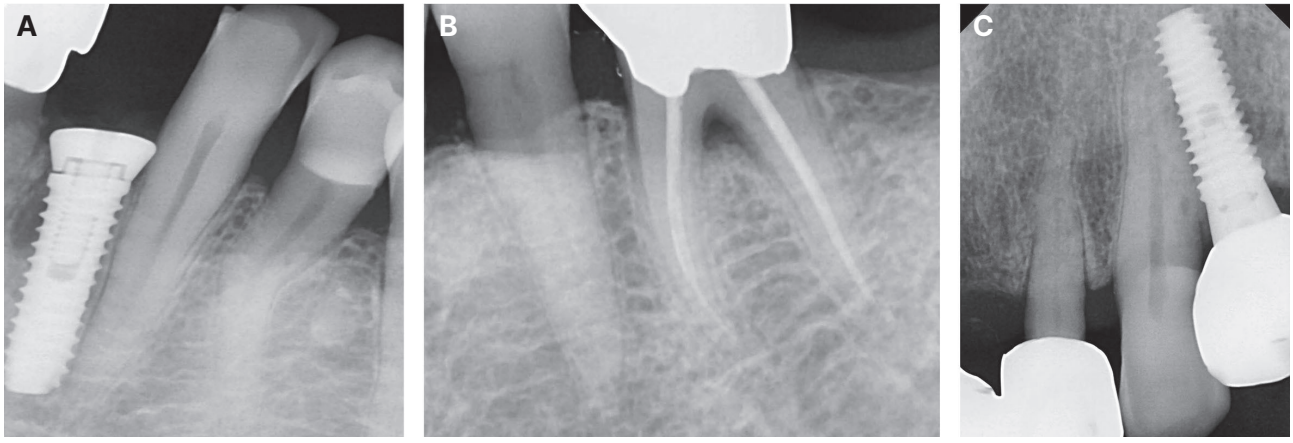

Fig. 2. (A) Periapical radiograph of implant placed at site #32 and adjacent tooth #33 demonstrating the absence of periapical pathology, (B) Tooth #36 with previous root canal treatment and evidence of furcation involvement, (C) Implant placed at site #24 in close proximity to the root surface of the adjacent maxillary canine (#23).

and completed over three appointments. After initiating endodontic therapy, the patient's symptoms were resolved completely, however, the tooth exhibited persistent, unexplained mobility. Therefore, CBCT (Dentsply Sirona, Bensheim, Germany) was obtained to evaluate possible implant-related injury and confirmed the absence of visible direct contact between the implant fixture and tooth #33 (Fig. 3). On tooth #33, working length was established at 23.5 mm (Fig. 4A), and canal instrumentation was performed using WaveOne Gold Medium NiTi files (Dentsply Maillefer, Ballaigues, Switzerland), followed by obturation with size #40 gutta-percha (Fig. 4B). Core build-up was completed using LuxaCore A3 (DMG America, Hamburg, Germany) and Filtek A3 (3M Oral Care, St. Paul, USA). 3-month follow-up is planned for monitoring mobility and root status.

During the appointments, the patient stated mild discomfort on #21, and additional evaluation identified a pre-existing implant in the maxillary left first premolar (#24), also placed at the same local clinic several years prior. The adjacent maxillary canine (#23) exhibited mild air sensitivity but responded normally to cold testing without lingering pain, and percussion tenderness was absent (Fig. 2C). Although this presentation appeared clinically similar to the mandibular #32 - 33 region, no radiographic or clinical evidence of pulpal pathology was found. The patient was advised to continue routine recall, with the understanding that root canal treatment on #23 would be indicated if symptoms progressed.

The patient returned to our clinic for a 3-month follow-up. At this visit, we observed that the mobility of tooth #33 had markedly decreased compared to previous examinations. The patient reported that the implant at site #32 became mobile approximately one month after completion of root canal treatment of tooth #33. The fixture was subsequently removed

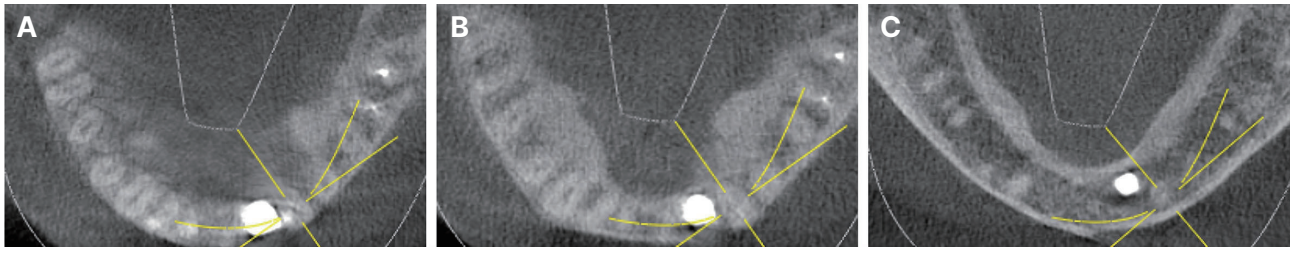

Fig. 3. CBCT images demonstrating no visible contact between the implant fixture at site #32 and the adjacent tooth #33. (A) Coronal third, (B) Middle third, (C) Apical third.

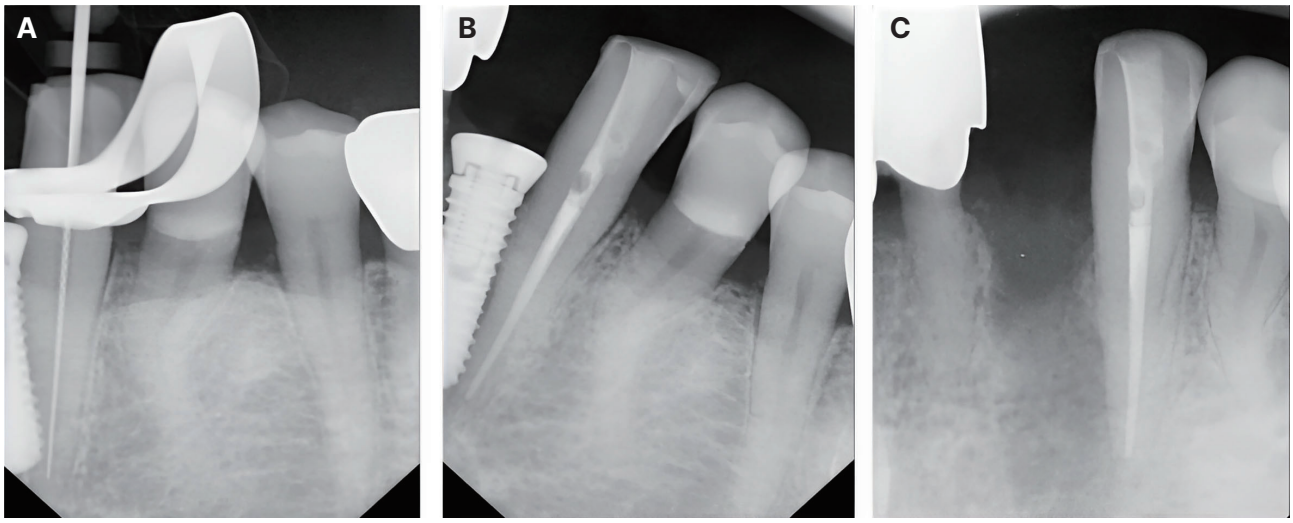

Fig. 4. (A) Working length radiograph during root canal treatment of tooth #33, (B) Post-obturation radiograph of tooth #33 with the adjacent implant at site #32, (C) Radiograph showing removal of the implant fixture from site #32.

by the original treating clinician. This temporal relationship raises the possibility that the implant placement procedure contributed to transient periodontal ligament injury in tooth #33 and supports a surgically induced traumatic etiology. Follow-up radiographs obtained at 3 months demonstrated absence of the implant fixture at site #32 with no periapical or peri-implant pathologic changes on #33 (Fig. 3C).

Discussion

This case represents an unusual clinical presentation in which irreversible pulpitis developed immediately after implant placement in an adjacent tooth without radiographic evidence of direct root damage. The diagnostic challenge in this case was further complicated for two reasons: first, in the absence of fixture-tooth contact as well as radiographic periapical changes, clinicians generally do not even consider pulpal degeneration in adjacent teeth; or if they do, they assume it would occur only after a longer period. A recent systematic review published in the Journal of Endodontics[3] synthesized evidence that implant placement may affect the health of adjacent roots and pulpal tissues. However, most reported cases have been documented only after radiographic changes became apparent, and reports considering pulpal degeneration in the absence of radiographic evidence at an early stage remain scarce. This highlights the rarity of our case, in which irreversible pulpitis developed immediately after implant placement without radiographic signs of fixture-tooth contact or periapical pathology. Second, the patient initially reported pain in the premolar-molar region despite normal findings in those teeth. Odontogenic pain may refer to teeth or other orofacial structures distant from the actual source, making localization difficult. In addition, systemic conditions, including chronic liver disease, have been reported to influence somatosensory processing and pain interpretation, potentially complicating accurate localization of odontogenic pain.[4,5] In the present case, the patient had a history of alcoholic cirrhosis with a prior episode of acute alcoholic hepatitis. Although systemic conditions such as chronic liver disease may potentially influence pain perception, the diagnosis was ultimately established through objective clinical findings and selective anesthesia.

Previous reports of implant-related pulpal complications have generally described delayed symptom onset, ranging from several months to two years, and were frequently associated with radiographic evidence of fixture-root contact or periapical pathology.[2,6,7] In contrast, the present case demonstrated symptomatic

irreversible pulpitis on the day of implant placement despite the absence of radiographic abnormalities. A retrospective study has shown that implant proximity to adjacent teeth can lead to pulpal devitalization or iatrogenic injury, even when radiographs appear clear.[2] The immediate onset of irreversible pulpitis in this case is more consistent with a surgically induced injury than with delayed bacterial leakage or secondary caries. This distinguishes the present case from previously reported delayed pulpal necrosis after implant placement. Several mechanisms may explain this rapid pulpal deterioration. First, excessive heat generation during drilling may cause thermal trauma to the pulp, particularly when the implant osteotomy is performed in close proximity to the root surface. The maximum allowable intrapulpal temperature increase has been suggested to be 5 - 7°C, above which irreversible pulpal injury may occur due to vascular stasis and neural damage.[8] Even without physical contact, cortical thinning near the root can reduce dentin insulation and heighten pulpal vulnerability. Second, microvascular compromise caused by surgical manipulation may lead to acute pulpal ischemia. Localized disruption of the neurovascular plexus or periodontal ligament supply can accelerate inflammatory progression.[9] Although radiographs did not reveal direct contact between the implant fixture and the root of tooth #33 in the present case, the anatomical closeness raises the possibility of inadvertent trauma during surgery. Notably, the mobility of tooth #33 decreased following removal of the adjacent implant. Although previous study has reported periodontal and pulpal complications associated with implant-root proximity or direct injury to adjacent teeth,[2] evidence regarding recovery of tooth mobility after implant removal remains limited. Therefore, a definitive causal relationship cannot be established. Nevertheless, the clinical improvement observed in the present case may suggest that the implant exerted a reversible mechanical influence on the periodontal supporting structures of the adjacent tooth.

Radiographic assessment alone would have failed to detect the early-stage pulpal injury. This emphasizes that clinical symptoms—particularly lingering cold response and percussion sensitivity—must guide diagnosis even when imaging findings are inconclusive. In this case, tooth #33 demonstrated an exaggerated response to cold testing and tenderness to percussion. Despite these findings, the patient persistently perceived the pain as originating from the posterior mandibular region. Therefore, a selective anesthetic test was performed by administering infiltration anesthesia in the mandibular canine region. The patient subsequently reported an approximately 60% reduction in pain intensity, supporting tooth #33 as the primary pain source. Although complete pain relief was not achieved, the result was considered supportive of the clinical diagnosis. The decision to initiate treatment was based primarily on the collective clinical findings including sensibility test, with the anesthetic test serving as an additional confirmatory procedure. Complete symptom resolution following root canal treatment further confirmed the pulpal origin of pain.

Conclusion

This case demonstrates that clinicians should maintain a high index of suspicion for pulpal complications when symptoms arise immediately after implant surgery. Comprehensive endodontic evaluation is essential, especially in patients with systemic conditions that may complicate pain assessment and interpretation. Prompt recognition of implant-adjacent pulpal injury can prevent unnecessary surgical interventions, shorten the duration of patient discomfort, and improve long-term treatment outcomes.

ORCID

Hee-Jin Kim https://orcid.org/0000-0003-4885-5879

References

1. Lin WS, Ercoli C, Morton D. Dental implant complications. In: Misch CE, editor. Dental implant prosthetics. 2nd ed. St. Louis; Elsevier; 2018. p. 1005-20.
2. Yi YJ, Park IW, Ku JK, Jo DW, Han JS, Kim YK. Long term clinical result of implant induced injury

on the adjacent tooth. Sci Rep 2021;11:7913.
3. Sabeti MA, Kim H. Effect of implants on the periapical health of natural adjacent teeth: a systematic review and meta-analysis. J Endod 2024;50:1705-13.
4. Holman A, Parikh N, Clauw DJ, Williams DA, Tapper EB. Contemporary management of pain in cirrhosis: Toward precision therapy for pain. Hepatology 2023;77:290-304.
5. Zhang NN, Wang ZY, Chen JM, Yan ZP, Ni GX, Ni J. Evaluation of Quantitative and Selective Sensory Fiber Dysfunction in Patients with Cirrhosis. Curr Neurovasc Res 2024;21:41-6.
6. Kim SG. Implant-related damage to an adjacent tooth: a case report. Implant Dent 2000;9:278-80.
7. Yoon WJ, Kim SG, Jeong MA, Oh JS, You JS. Prognosis and evaluation of tooth damage caused by implant fixtures. J Korean Assoc Oral Maxillofac Surg 2013;39:144-7.
8. Lau XE, Liu X, Chua H, Wang WJ, Dias M, Choi JJE. Heat generated during dental treatments affecting intrapulpal temperature: a review. Clin Oral Investig 2023;27:2277-97.
9. Andreasen JO, Andreasen FM. Pulpal sequelae of acute dental trauma. In: Andreasen JO, Andreasen FM, editors. Textbook and color atlas of traumatic injuries to the teeth. 4th ed. Oxford; Blackwell Munksgaard; 2007. p. 457-79.

방사선학적 치근 접촉 소견 없이 임플란트 식립 직후 발생한 인접치의 증상성 비가역성 치수염: 진단적 난제

김희진* 부교수

고신대학교 의과대학 치과학교실

본 증례는 즉시 임플란트 식립 후 인접 치아에서 발생한 드문 초기 치수 합병증을 보고한다. 알코올성 간염을 가진 환자가 #32 부위에 임플란트를 식립한 직후부터 지속적인 불편감을 호소하였다. 초기 치주 치료는 실패하였으며, 이후 의뢰 과정에서 #34 치아에 통증을 호소하였고, 본원에 내원하여 치수생활력 검사 결과, 방사선학적 병변이나 임플란트-치근 접촉이 없음에도 불구하고 인접 치아 #33에서 비가역적 치수염이 진단되었다. 근관치료 후 제반 증상이 소실되었으며, 이후 임플란트 제거하고 재내원 시 #33의 동요도 또한 감소되었음을 확인하였다. 본 증례는 임플란트 식립 후 인접 치아에서 방사선학적 징후 없이도 치수 손상이 발생할 수 있으며, 특히 통증 인지가 변화된 전신질환 환자에서는 오인된 통증 양상으로 나타날 수 있음을 강조한다. 또한 즉시 발생한 비가역적 치수염은 기존에 보고된 지연성 합병증과 구별되며, 임플란트 식립 후 지속적 증상이 나타날 경우 인접 치아의 치수 상태에 대한 면밀한 평가가 필요함을 시사한다.

(구강회복응용과학지 2026;42(3):271-7)

주요어: 증상성 비가역성 치수염; 임플란트 유발 손상; 알코올성 간염; 연관통

*교신저자: 김희진
(49267)부산광역시 서구 감천로 262 고신대학교 의과대학 치과학교실
Tel: 051-990-6260 | Fax: 051-990-3005 | E-mail: island719@naver.com
접수일: 2026년 5월 9일 | 수정일: 2026년 6월 8일 | 채택일: 2026년 6월 8일