https://doi.org/10.14368/jdras.2026.42.3.299
ISSN 2384-4353 eISSN 2384-4272

Case Report

Healing abutment-supported custom caps for maxillomandibular relationship record in multiple implant-supported restorations: a case report

Seoyeon Park*
Department of Prosthodontics, Daejeon Dental Hospital, Wonkwang University, Daejeon, Republic of Korea

Accurate recording of the maxillomandibular relationship is important for prosthetic outcomes in multiple implant-supported restorations. In general, the maxillomandibular relationship is recorded after fabrication of the master cast. However, when the relationship is recorded at an earlier stage to simplify the prosthetic procedure, a stable supporting structure is required. In this case, CAD/CAM healing abutment-supported custom caps were fabricated for a patient with a few remaining teeth and connected to record bases with occlusal rims to record the maxillomandibular relationship at an early stage. This allowed stable intraoral placement of the record bases, followed by impression making and prosthesis fabrication. After delivery of the definitive prostheses, stable bilateral occlusal contacts and group function during lateral movements were confirmed. Functional and esthetic outcomes were maintained during the follow-up period. This case suggests that healing abutment-supported custom caps may provide an alternative means of recording the maxillomandibular relationship without requiring a master cast. **(J Dent Rehabil Appl Sci 2026;42(3):299-308)**

Key words: implant restoration; healing abutment; maxillomandibular relationship; impression

Introduction

In extensive implant-supported fixed prosthetic rehabilitation, accurate determination and recording of a stable maxillomandibular relationship are critical to achieving satisfactory functional and esthetic outcomes.[1] This is particularly challenging in completely or partially edentulous patients who lack posterior occlusal support because stable occlusal contacts are unavailable as reference points. Therefore, reliable determination of the vertical dimension of occlusion and centric relation and accurate transfer of this information to the laboratory are essential.[2,3]

In a conventional implant prosthetic workflow, the clinical and laboratory sequence includes preliminary impression making, custom tray fabrication, final impression making, and maxillomandibular relationship recording using record bases and occlusal rims fabricated on the master casts. Although this sequence provides stable support for registration, it requires an additional clinical appointment and laboratory step dedicated specifically to recording the maxillomandibular relationship.[2] Accordingly, various methods have been proposed to allow registration at an earlier stage and streamline the overall restorative process.[4,5]

Before master cast fabrication, existing prostheses that accurately reflect the established occlusal relationship may serve as references. However, such

*Correspondence to: Seoyeon Park
Clinical Assistant Professor, Department of Prosthodontics, Daejeon Dental Hospital, Wonkwang University, 77 Doonsan-ro, Seo-gu, Daejeon, 35233, Republic of Korea
Tel: +82-42-366-1164, Fax: +82-42-366-1115, E-mail: 7646psy@naver.com
Received: July 2, 2026/Last Revision: July 22, 2026/Accepted: July 30, 2026

Copyright© 2026 The Korean Academy of Stomatognathic Function and Occlusion.
©It is identical to Creative Commons Non-Commercial License.

approaches depend on the availability of a stable occlusal relationship, a well-fitting denture base or a custom tray.[4] When support is derived from soft tissue, mucosal displacement or changes in tissue morphology may affect the accuracy of the record.[5] By contrast, when a record base or occlusal rim is supported by the implants, final impression making and master cast fabrication are generally required beforehand.[5-7]

In the present case, healing abutments were used as supporting structures to record the maxillomandibular relationship instead of relying on soft tissue support. CAD/CAM (computer-aided design/computer-aided manufacturing) custom caps were fabricated based on the contours of the healing abutments and connected to the record bases with occlusal rims, enabling registration of the maxillomandibular relationship before the master cast became available. Fig. 1 schematically compares the conventional and proposed prosthetic workflows. This case report describes an implant-supported fixed prosthetic rehabilitation in which the maxillomandibular relationship was recorded using healing abutment-supported custom caps before fabrication of the master cast.

Case Report

A 75-year-old woman presented with discomfort during denture use and requested implant-supported fixed rehabilitation. The patient had received a maxillary complete denture and a mandibular removable partial denture at another dental clinic within the previous year. However, she was not using the maxillary denture because it caused gagging. She had been chewing only with the remaining mandibular teeth. Clinical examination revealed a completely edentulous maxilla and three remaining mandibular teeth. The mandibular right first premolar, right canine, and left canine had been restored with surveyed crowns (Fig. 2). Radiographic examination revealed severe alveolar bone resorption and maxillary sinus pneumatization (Fig. 3A). Extraoral examination revealed facial features commonly observed in edentulous patients, including reduced lower facial height and insufficient lip support (Fig. 3B, 3C). No abnormalities were noted in the temporomandibular joints or masticatory muscles. Considering the patient's age and treatment needs, the treatment plan was to preserve the remaining teeth and restore the edentulous

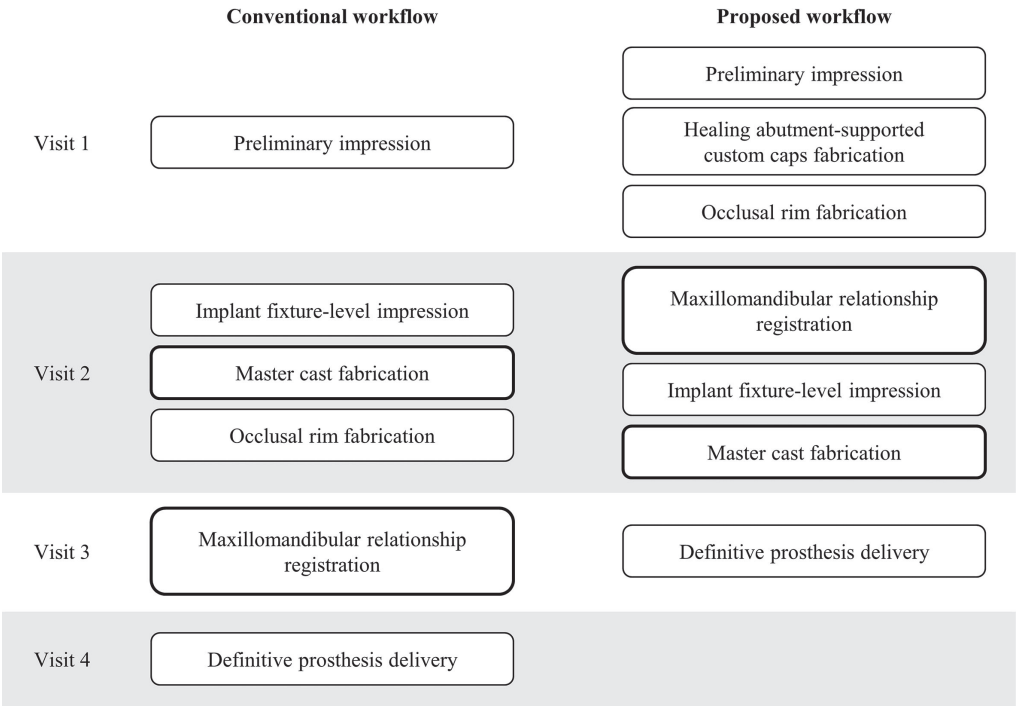

Fig. 1. Schematic diagram of conventional and proposed workflows for maxillomandibular relationship registration.

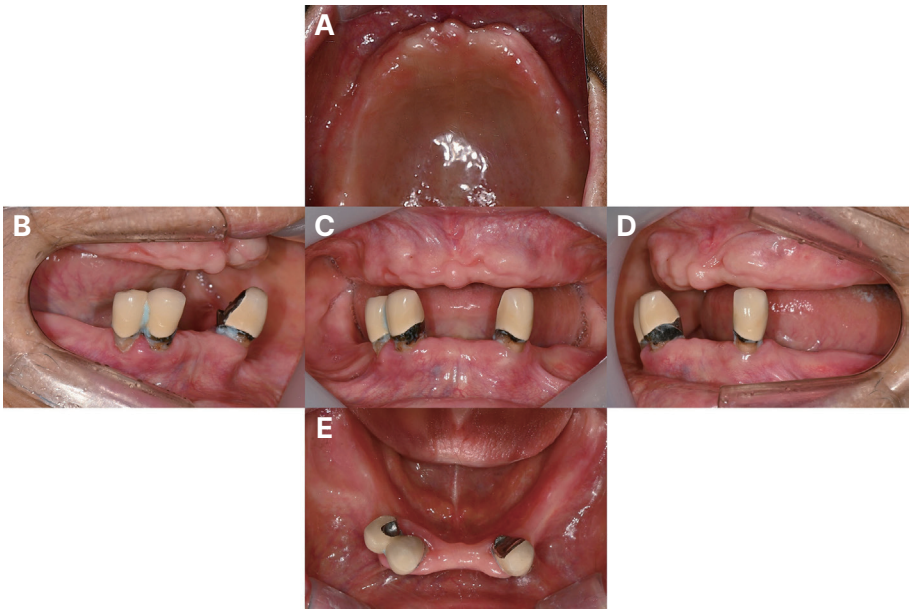

Fig. 2. Pretreatment intraoral photographs. (A) Maxillary occlusal view, (B) Right lateral view, (C) Frontal view, (D) Left lateral view, (E) Mandibular occlusal view.

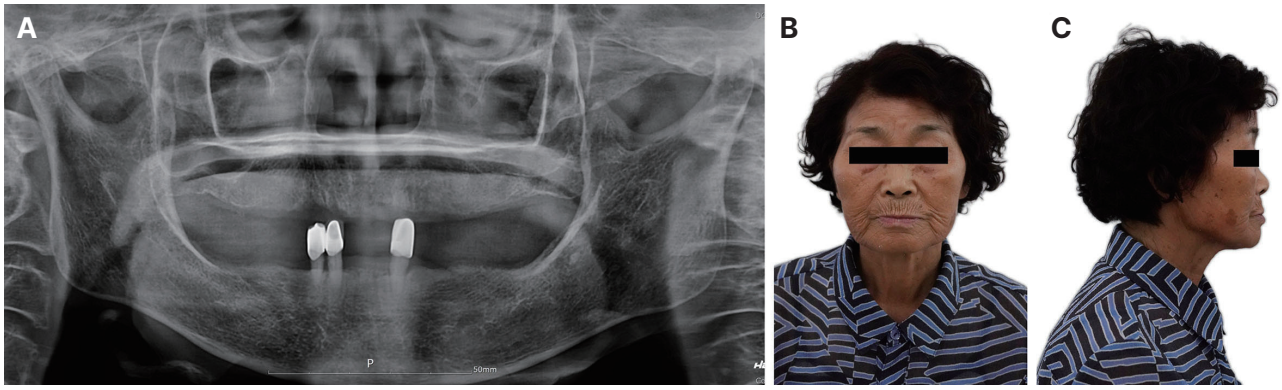

Fig. 3. Pretreatment images. (A) Panoramic radiograph, (B) Frontal extraoral view, (C) Lateral profile view.

regions with implant-supported prostheses extending to the first molar region.[8]

Internal-connection implants (Osstem TSIII, Osstem Implant, Seoul, Korea) were placed and allowed to osseointegrate for approximately 4 months. After second-stage implant surgery, the patient returned for prosthetic treatment with healing abutments in place. The implant stability quotient (ISQ) values were 75 or higher, and no abnormal clinical or radiographic findings were noted (Fig. 4A - 4C). Preliminary impressions were then made to fabricate custom trays for final impressions.

Healing abutment-supported custom caps, hereafter referred to as custom caps, were fabricated to stabilize the occlusal rims during recording of the maxillomandibular relationship. The contours of the healing abutments were scanned with a model scanner (Medit T500; Medit, Seoul, Korea), and the custom caps were designed using CAD software (Meshmixer; Autodesk, San Rafael, USA). Each cap consisted of a circular lower portion that seated passively on the healing abutment and a rectangular upper portion with retention grooves for connection to the record base (Fig. 5A). To create the internal space

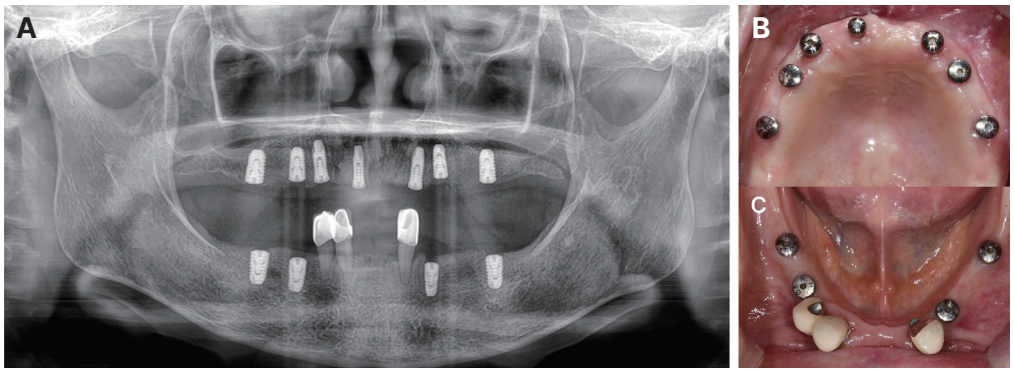

Fig. 4. Images after implant placement. (A) Panoramic radiograph, (B) Maxillary occlusal view, (C) Mandibular occlusal view.

for the healing abutment, the scanned geometry of the healing abutment was superimposed on and subtracted from the cap design (Fig. 5B). The lower portion allowed passive seating without mechanical fixation and was designed to cover only the parallel-sided portion of the healing abutment without extending onto its apically tapered portion, whereas the upper portion was modeled after a plastic cap used with an impression transfer coping. The lower portions were verified to be free of undercuts before the caps were milled from polymethyl methacrylate (PMMA) (Fig. 5C). The custom caps were then seated on the healing abutments on the preliminary casts, and approximately 1-mm-thick baseplate wax was adapted circumferentially around each cap to provide relief between the caps and the record bases (Fig. 6A). Record bases were fabricated from light-polymerizing resin (Plaque Photo®; WP Dental, Barmstedt, Germany) to allow connection to the upper portions of the caps. Occlusal rims were then fabricated from baseplate wax. Four maxillary and three mandibular healing abutments were selected as support sites for the occlusal rims.

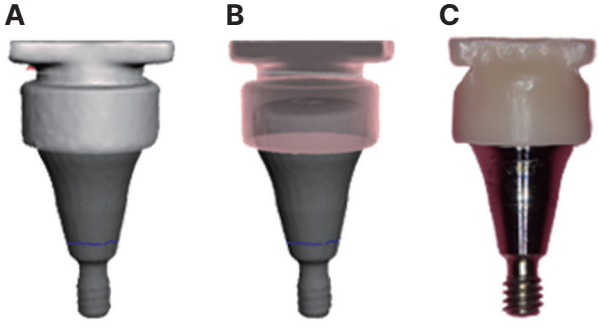

Fig. 5. CAD/CAM design and fabrication of a healing abutment-supported custom cap. (A) External view of the custom cap design, (B) Superimposed view of the healing abutment and custom cap design, (C) Milled PMMA custom cap.

At the next visit, the maxillomandibular relationship was recorded. Before intraoral placement of the custom caps, the implant fixture and healing abutment at the 16i site were found to be distally inclined, making it difficult to insert and remove the corresponding cap along the same path of insertion as the others. Therefore, the distal wall of the corresponding cap was removed to permit insertion and removal along that path while maintaining vertical support from the upper portion (Fig. 6A, 6B). During adjustment of the occlusal plane and vertical dimension of occlusion, the record bases with occlusal rims were repeatedly inserted and removed. The occlusal plane of the maxillary rim was adjusted to be parallel to the interpupillary and ala-tragus lines. The vertical dimension of occlusion was then established by considering function, phonetics, and facial appearance (Fig. 6C).

Once the occlusal rims were seated, bilateral pressure was applied to the right and left sides with the index fingers to confirm the absence of rocking or visible movement of the custom caps. The internal space of the record bases was then filled with dual-cure composite resin, and the caps were connected to the record bases intraorally (Fig. 6D). After polym-

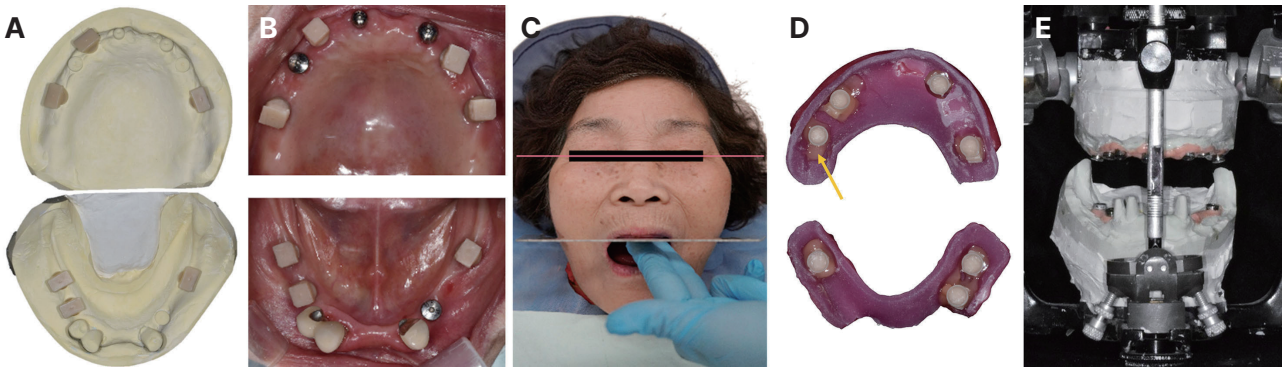

Fig. 6. Clinical application of the healing abutment-supported custom caps. (A) Custom caps seated on the healing abutments on the preliminary casts, (B) Intraoral seating of the custom caps on the healing abutments, (C) Evaluation of the maxillary occlusal plane using an occlusal plane guide, (D) Record bases with occlusal rims after intraoral connection to the custom caps using composite resin (arrow), (E) Master casts mounted on a semiadjustable articulator using the maxillomandibular relationship record obtained with the healing abutment-supported custom caps.

erization, the occlusal plane and vertical dimension of occlusion were reassessed and confirmed to be unchanged. An interocclusal record was made with Aluwax (Aluwax Dental Products Co., Grand Rapids, USA), and the assembly was then removed from the mouth.

After recording the maxillomandibular relationship, final impressions were made at the fixture level using the pick-up impression technique with the previously fabricated custom trays. Healing abutments identical to those used intraorally were connected to the master casts, and the casts were mounted on a semiadjustable articulator (Hanau Modular Articulator; Whip Mix, Louisville, USA) using the interocclusal record. Titanium custom abutments and PMMA provisional restorations (VIPI block; VIPI Industria, São Paulo, Brazil) were fabricated and delivered. Bilateral occlusal contacts were established in centric relation, and the occlusion was adjusted to provide group function during lateral movements (Fig. 7).

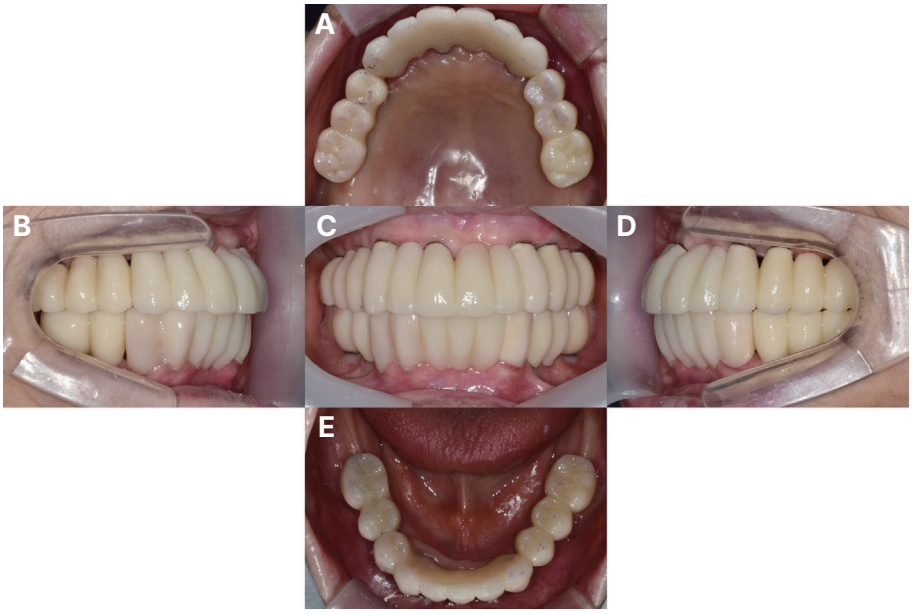

Fig. 7. Provisional restoration. (A) Maxillary occlusal view, (B) Right lateral view, (C) Frontal view, (D) Left lateral view, (E) Mandibular occlusal view.

After an adaptation period of more than 3 months, the provisional restoration and remaining dentition were scanned intraorally (Trios 4; 3Shape, Copenhagen, Denmark) to transfer the contours and occlusal scheme of the provisional restoration to the definitive prostheses (Fig. 8A). To provide reference points for image superimposition and alignment, an additional scan of the abutments and abutment teeth was made after removal of the anterior segment of the provisional restoration (Fig. 8B). The remaining posterior prostheses were then removed, and abutment-level impressions were made (Fig. 8C, 8D). Using a previously described digital transfer approach, the definitive prostheses were fabricated based on the information obtained from the provisional restoration. At delivery, stable bilateral occlusal contacts and group function during lateral movements were confirmed, and satisfactory functional and esthetic outcomes were achieved (Fig. 9). Clinical examinations showed favorable function and well-maintained prostheses, and facial support was improved by the implant-supported prostheses (Fig. 10).

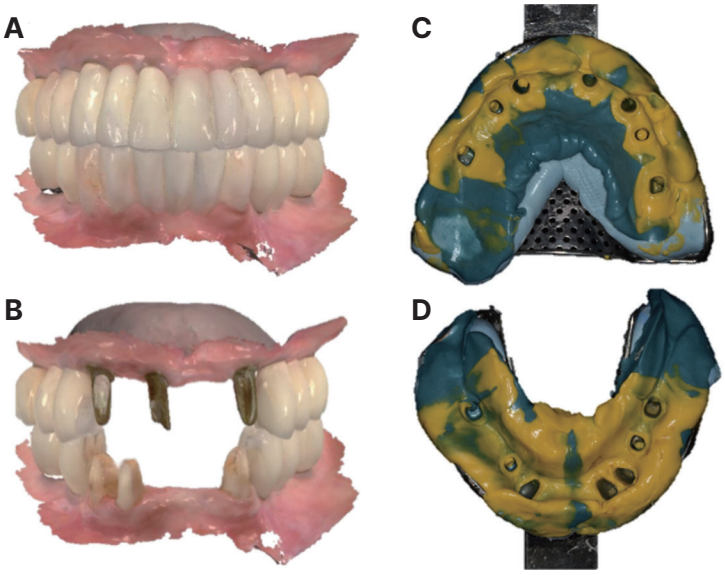

Fig. 8. Final impression procedure. (A) Intraoral scan of the provisional restorations, (B) Intraoral scan after removal of the anterior segments of the provisional restorations, (C) Maxillary abutment-level impression, (D) Mandibular abutment-level impression.

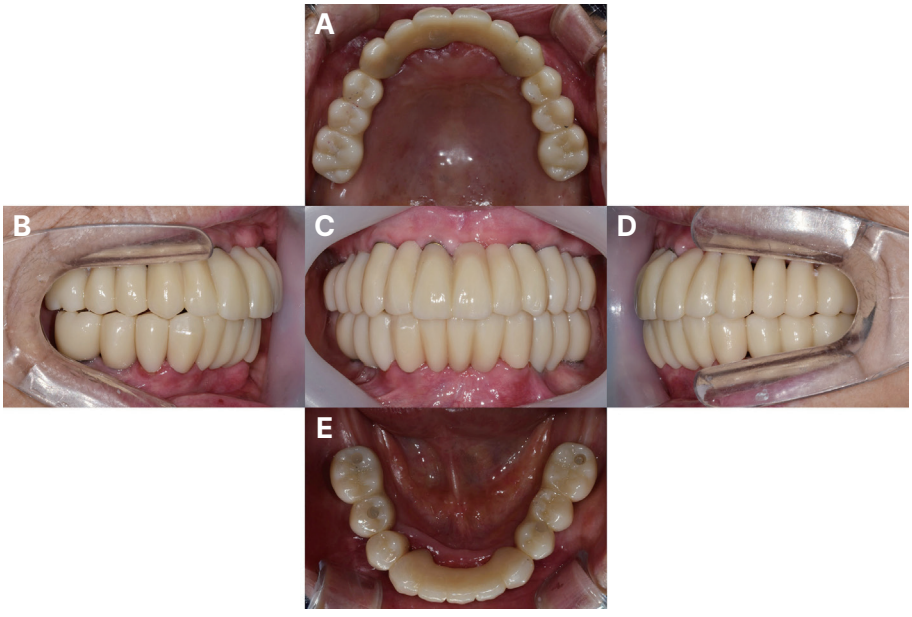

Fig. 9. Definitive restoration. (A) Maxillary occlusal view, (B) Right lateral view, (C) Frontal view, (D) Left lateral view, (E) Mandibular occlusal view.



Fig. 10. Post-treatment extraoral images. (A) Frontal view, (B) Profile view.

Discussion

Healing abutment-supported custom caps and occlusal rims were used to record the maxillomandibular relationship prior to fabrication of the master cast in a patient. In a conventional workflow for prosthetic rehabilitation involving multiple implants, this relationship is generally recorded using record bases and occlusal rims fabricated on master casts obtained from fixture-level impressions.[2,5-7] Although this approach provides stable support during recording, it requires additional laboratory and clinical procedures, which may prolong treatment and increase the number of visits. Patil and Nimbalkar-Patil[9] described a method for recording the maxillomandibular relationship with healing abutments in place. Although the technique can reduce the need for removal and reconnection of healing abutments, fabrication of the record base on a master cast obtained from a fixture-level impression is still required.

Several methods using existing dentures or interim prostheses have also been described for recording the maxillomandibular relationship during final impression making.[10,11] However, these methods are more readily applicable when a stable occlusal relationship has already been established with an existing denture or interim prosthesis, or when a well-fitting denture base can be used as a reference.[10] Therefore, in patients for whom an existing prosthesis cannot serve as a reliable reference, an additional supporting structure is required for stable recording of the maxillomandibular relationship before the final impression stage. In the present case, the custom caps were supported by the healing abutments rather than soft tissue, thereby helping to stabilize the record bases and occlusal rims. Consequently, final impressions could be made and the maxillomandibular relationship recorded at the same visit.

However, this technique was not compared with a record base supported directly by the healing abutments without custom caps. Therefore, no claim of greater accuracy can be made for this technique. Instead, the custom caps were used as intermediary components that allowed the seating of each cap on its corresponding healing abutment to be verified individually and provided retentive surfaces for connection to the record bases. Thus, the intended advantage of the custom caps was not greater accuracy, but rather the ability to verify their seating on the healing abutments and connect them to the record bases.

One important design consideration in this technique was to achieve complete and consistent seating of the custom caps on the healing abutments while providing a stable connection to the record bases. Because record bases are repeatedly inserted, removed, and adjusted intraorally, positional changes during these procedures may affect the recording of the maxillomandibular relationship.[2,12] The internal surface of the rectangular upper portion of each cap contacted the coronal surface of the corresponding healing abutment and served as a vertical stop during seating. The internal axial surfaces of the circular lower portion guided the cap into complete seating and limited horizontal displacement. No separate feature to prevent rotation was incorporated into each cap. Instead, resistance to rotation was provided by connecting the caps to the record base as a single assembly. The caps were designed to seat passively on the healing abutments rather than being mechanically fixed, and undercuts were eliminated to allow insertion and removal without interference. Before the caps were connected intraorally to the record bases, relief spaces within the record bases prevented

mechanical engagement with the upper portions of the caps, allowing the record bases to be inserted and removed without dislodging the caps. In contrast, retention features were incorporated into the upper portion of each cap to allow each record base and its corresponding caps to function as a single rigid assembly once connected with dual-cure resin. The multiple points of support provided by the connected caps helped limit rotation and horizontal displacement of the record base.[13] Accordingly, the paths of insertion and removal of the individual caps had to be coordinated. At the 16i site, the distal inclination of the implant made it difficult to establish a common path of insertion. Therefore, the distal wall of the corresponding cap was removed to allow insertion along the common path while maintaining vertical support (Fig. 6A, 6B). The need for this modification suggests that the application of this technique may be limited in cases of marked implant divergence.[14]

This technique has several limitations. First, the vertical space required for the custom caps and record bases must be considered. Available vertical restorative space may be greater in patients with long-term edentulism and severe alveolar bone resorption but may be limited soon after tooth extraction, when a substantial portion of the alveolar process remains intact.[15] Limited vertical restorative space may make it difficult to achieve sufficient stability of the caps and record bases. In the present case, considerable maxillary alveolar bone resorption provided sufficient space to accommodate the caps and occlusal rims. In patients with limited space, however, design modifications, such as reducing the thickness of the record base or decreasing the height of the caps, may be required. Second, the shape of the upper portion of the cap requires further consideration. In the present case, the upper portion was rectangular to enhance its connection to the record base. However, this shape increased the space required for record base fabrication and may have increased the risk of interference along the path of insertion. A smaller, lower-profile upper portion may be advantageous when the available restorative space is limited.[16] A circular form with less potential for interference during insertion and removal may also broaden the clinical applicability of this technique. Third, fabrication of the custom caps requires additional scanning, design, and milling procedures, and inaccuracies arising during these procedures may affect their fit of the caps.[17] Therefore, the complete seating and passive fit of each cap should be verified on the preliminary cast and intraorally before connection to the record base. These additional fabrication procedures represent a limitation compared with direct adaptation of the record base to the healing abutments. Finally, the accuracy of the maxillomandibular relationship recorded using the custom caps was not quantitatively compared with that of conventional methods. Therefore, additional cases and comparative studies are needed to evaluate the reproducibility and accuracy of this technique.

Despite these limitations, the custom caps enabled the maxillomandibular relationship to be recorded before fabrication of the master cast in this patient, whose existing dentures could not serve as reliable references. In particular, the record obtained before fixture-level impression making was subsequently used to mount the master casts and fabricate the interim prostheses. After functional adaptation and occlusal evaluation with the provisional restoration, the acquired information was incorporated into the definitive prostheses. The planned occlusal scheme was maintained after delivery, and no notable clinical or prosthetic complications were observed during the approximately 3-month follow-up period.

Conclusion

In this case, healing abutment-supported custom caps were used to record the maxillomandibular relationship before master cast fabrication in a patient requiring multiple implant-supported restorations whose existing dentures could not serve as reliable references. When adequate inter-arch space is available and implant divergence and the paths of insertion of the caps are carefully assessed during cap design, this technique may provide an alternative method for recording the maxillomandibular relationship without requiring a master cast.

ORCID

Seoyeon Park https://orcid.org/0009-0003-1532-5107

References

1. Warren K, Capp N. A review of principles and techniques for making interocclusal records for mounting working casts. Int J Prosthodont 1990;3:341-8.
2. Freilich MA, Altieri JV, Wahle JJ. Principles for selecting interocclusal records for articulation of dentate and partially dentate casts. J Prosthet Dent 1992;68:361-7.
3. Rungcharassaeng K, Kan JY. Fabricating a stable record base for completely edentulous patients treated with osseointegrated implants using healing abutments. J Prosthet Dent 1999;81:224-7.
4. Vahidi F. The provisional restoration. Dent Clin North Am 1987;31:363-81.
5. Park DH, Park JM, Choi JW, Kang ES, Bae EB, Jeon YC, Jeong CM, Yun MJ, Huh JB. Accuracy of several implant bite registration techniques: an in-vitro pilot study. J Adv Prosthodont 2017;9:341-9.
6. Savabi O, Yosefimoghadam A, Nejatidanesh F. A method for making the implant-supported record bases. J Oral Implantol 2009;35:300-2.
7. Petridis HP. Stable interocclusal records for implant patients with posterior edentulism. J Prosthet Dent 2004;92:503.
8. Kanno T, Carlsson GE. A review of the shortened dental arch concept focusing on the work by the Käyser/Nijmegen group. J Oral Rehabil 2006;33:850-62.
9. Patil PG, Nimbalkar-Patil S. Maxillomandibular relationship record for complete arch/mouth implant restorations using putty-elastomeric occlusal rim at healing abutment level. Contemp Clin Dent 2015;6:318-20.
10. Kurahashi K, Matsuda T, Goto T, Ishida Y, Ito T, Ichikawa T. Duplication of complete dentures using general-purpose handheld optical scanner and 3-dimensional printer: Introduction and clinical considerations. J Prosthodont Res 2017;61:81-6.
11. Burns DR, Beck DA, Nelson SK; Committee on Research in Fixed Prosthodontics of the Academy of Fixed Prosthodontics. A review of selected dental literature on contemporary provisional fixed prosthodontic treatment: report of the Committee on Research in Fixed Prosthodontics of the Academy of Fixed Prosthodontics. J Prosthet Dent 2003;90:474-97.
12. Keith SE, Guillen GE. Enhanced stability for implant-supported overdenture record bases. J Prosthet Dent 1998;79:359-60.
13. Abduo J, Palamara JEA. Accuracy of digital impressions versus conventional impressions for 2 implants: an in vitro study evaluating the effect of implant angulation. Int J Implant Dent 2021;7:75.
14. Richi MW, Kurtulmus-Yilmaz S, Ozan O. Comparison of the accuracy of different impression procedures in case of multiple and angulated implants: Accuracy of impressions in multiple and angulated implants. Head Face Med 2020;16:9.
15. AbuJamra NF, Stavridakis MM, Miller RB. Evaluation of interarch space for implant restorations in edentulous patients: a laboratory technique. J Prosthodont 2000;9:102-5.
16. Pasciuta M, Grossmann Y, Finger IM. A prosthetic solution to restoring the edentulous mandible with limited interarch space using an implant-tissue-supported overdenture: a clinical report. J Prosthet Dent 2005;93:116-20.
17. Pan Y, Tsoi JKH, Lam WYH, Zhao K, Pow EHN. The cumulative effect of error in the digital workflow for complete-arch implant-supported frameworks: An in vitro study. Clin Oral Implants Res 2022;33:886-99.

치유지대주 지지 맞춤형 캡을 이용한 임플란트 전악 수복에서의 상하악관계기록

박서연* 임상진료조교수
원광대학교 치과대학 대전치과병원 치과보철과

다수의 임플란트 수복에서 정확한 상하악관계의 기록은 보철 결과에 중요한 영향을 미친다. 일반적으로 상하악관계의 기록은 주모형 제작 이후에 시행되며, 과정을 단순화하기 위해 그 이전 단계에서 상하악관계를 채득하고자 하는 경우에는 안정적인 지지 구조가 필요하다. 본 증례에서는 소수의 잔존치를 가진 환자에서 치유지대주를 지지 구조로 활용한 CAD/CAM 맞춤형 캡을 제작하고, 기록상 및 교합제와 연결하여 주모형 제작 이전에 상하악관계를 채득하였다. 이를 통해 기록상을 안정적으로 유지할 수 있었으며, 인상 채득과 보철물 제작을 진행하였다. 최종 보철 후 안정적인 양측성 교합 접촉과 측방 운동 시 군기능 교합 양상이 확인되었고, 추적 관찰 기간 동안 기능적·심미적으로 양호한 결과가 유지되었다. 본 증례는 맞춤형 치유지대주 캡이 임플란트 수복에서 상하악관계기록을 안정화하고 보철 과정을 단순화하는 데 도움이 될 수 있음을 보여준다.

(구강회복응용과학지 2026;42(3):299-308)

주요어: 임플란트 수복; 치유지대주; 상하악관계; 인상채득

*교신저자: 박서연
(35232)대전광역시 서구 둔산로 77 원광대학교 치과대학 대전치과병원 치과보철과
Tel: 042-366-1164 | Fax: 042-366-1115 | E-mail: 7646psy@naver.com
접수일: 2026년 7월 2일 | 수정일: 2026년 7월 22일 | 채택일: 2026년 7월 30일